A 15-year-old boy comes to the office due to right ear itching and discomfort for the past several days. He has no fever or hearing loss but has noted scant drainage of thin, whitish fluid. The patient has been taking swimming lessons at a local gym. On examination, there is no redness around the ear, but gentle traction of the pinna elicits pain. During inspection of the external auditory canal, a speculum is inserted into the meatus in close contact with its posterior wall, causing the patient to suddenly become lightheaded and faint. He recovers spontaneously within a few minutes with no residual confusion. Which of the following nerves was most likely irritated during the procedure?

A. Accessory

B. Facial

C. Trigeminal

D. Vagus

E. Vestibulocochlear

Submit

A 15-year-old boy comes to the office due to right ear itching and discomfort for the past several days. He has no fever or hearing loss but has noted scant drainage of thin, whitish fluid. The patient has been taking swimming lessons at a local gym. On examination, there is no redness around the ear, but gentle traction of the pinna elicits pain. During inspection of the external auditory canal, a speculum is inserted into the meatus in close contact with its posterior wall, causing the patient to suddenly become lightheaded and faint. He recovers spontaneously within a few minutes with no residual confusion. Which of the following nerves was most likely irritated during the procedure?

- A. Accessory (0%)
- B. Facial (10%)
- C. Trigeminal (6%)
- ✓ D. Vagus (50%)
- E. Vestibulocochlear (32%)

Omitted
Correct answer
D

50%
Answered correctly

03 secs
Time Spent

05/31/2020
Last Updated

Explanation

Cutaneous innervation of the ear

Explanation

Cutaneous innervation of the ear

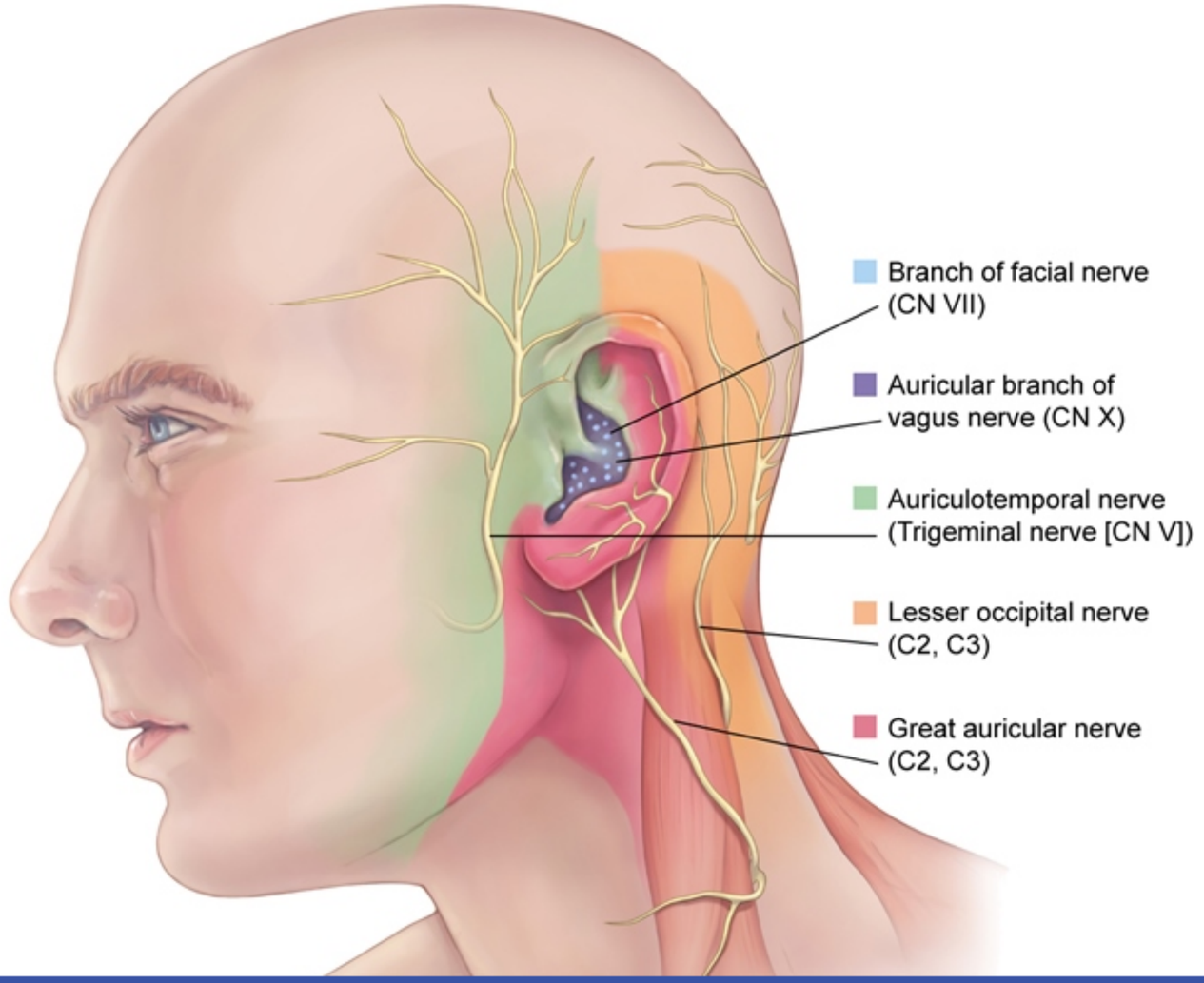

The majority of the external ear receives cutaneous innervation from the great auricular nerve, lesser occipital nerve, and auriculotemporal nerve. Most of the external auditory canal, including the external portion of the tympanic membrane, is innervated by the mandibular division of the trigeminal nerve (cranial nerve [CN] V3) via its auriculotemporal branch.

However, the **posterior** part of the **external auditory canal**, as well as the concavity and posterior eminentia of the concha, is innervated by the small auricular branch of the **vagus nerve** (CN X). This patient has experienced **vasovagal syncope** after stimulation of his posterior external auditory canal by an otoscope speculum. In this form of syncope, parasympathetic outflow via the vagus nerve leads to decreased heart rate and blood pressure.

(Choice A) The accessory nerve (CN XI) provides voluntary motor innervation to the trapezius and the sternocleidomastoid.

(Choice B) The facial nerve (CN VII) has a small motor component to the stapedius and muscles behind the ear. It supplies cutaneous sensation to a small area of the auricle, but stimulation here would be unlikely to trigger a vasovagal response.

(Choice C) The mandibular branch of the trigeminal nerve carries sensation from the majority of the external auditory meatus, except for the posterior wall.

(Choice E) The vestibulocochlear nerve (CN VIII) mediates hearing and vestibular proprioception. It does not mediate any cutaneous sensation.

Educational objective:
The vagus nerve provides cutaneous sensation to the posterior external auditory canal via its small auricular branch. Sensation to the rest of the canal is from the mandibular division of the trigeminal nerve.

Anatomy	Ear, Nose & Throat (ENT)	Otitis externa
Subject	System	Topic

Copyright © UWorld. All rights reserved.

A 50-year-old man comes to the office due to a lump in his neck that has been present for 4 months and is enlarging. On examination, there is a firm, nontender, nonmobile mass in the right anterior neck. Otoscopic examination shows a clear right middle ear effusion. Needle biopsy of the neck mass is consistent with regional nodal spread of squamous cell carcinoma. Which of the following is the most likely site of the primary tumor?

A. Base of tongue
B. Nasopharynx
C. Parotid gland
D. Piriform sinus
E. Thyroid gland
F. Vocal cord

Submit

A 50-year-old man comes to the office due to a lump in his neck that has been present for 4 months and is enlarging. On examination, there is a firm, nontender, nonmobile mass in the right anterior neck. Otoscopic examination shows a clear right middle ear effusion. Needle biopsy of the neck mass is consistent with regional nodal spread of squamous cell carcinoma. Which of the following is the most likely site of the primary tumor?

- A. Base of tongue (23%)
- ✓ B. Nasopharynx (40%)
- C. Parotid gland (8%)
- D. Piriform sinus (3%)
- E. Thyroid gland (6%)
- F. Vocal cord (18%)

Omitted
Correct answer
B

40%
Answered correctly

03 secs
Time Spent

02/27/2020
Last Updated

Explanation

Squamous cell carcinoma that originates in the mucosa of the head and neck typically spreads first to the **anterior cervical lymph nodes**. An enlarged, firm cervical lymph node is often the presenting symptom of head and neck squamous cell carcinoma (HNSCC). Identification of the primary site of tumor formation is important for staging and to guide treatment strategies.

This patient's **unilateral middle ear effusion** suggests **obstruction** of the **eustachian tube**, which connects the middle ear space to the nasopharynx. It opens intermittently, typically during swallowing or yawning to equalize pressure in the middle ear. Failure to adequately open

Squamous cell carcinoma that originates in the mucosa of the head and neck typically spreads first to the **anterior cervical lymph nodes**. An enlarged, firm cervical lymph node is often the presenting symptom of head and neck squamous cell carcinoma (HNSCC). Identification of the primary site of tumor formation is important for staging and to guide treatment strategies.

This patient's **unilateral middle ear effusion** suggests **obstruction** of the **eustachian tube**, which connects the middle ear space to the nasopharynx. It opens intermittently, typically during swallowing or yawning to equalize pressure in the middle ear. Failure to adequately open causes negative pressure to build within the middle ear, leading to a transudative effusion (clear, amber, or yellow). Eustachian tube dysfunction can be due to anatomic obstruction from a **mass in the nasopharynx** or, more commonly, due to functional obstruction from infections, allergic rhinitis, or irritants (eg, tobacco smoke).

(Choices A, D, and F) HNSCC can originate from the mucosa of other anatomic sites. Many sites (eg, base of tongue, piriform sinus) initially cause only vague or minor symptoms, but some may present with more specific features (eg, hoarseness in vocal cord cancer). Cancer at any of these other sites (ie, base of tongue, piriform sinus, vocal cord) would not lead to obstruction of the eustachian tube with a resultant middle ear effusion.

(Choice C) Cancer of the parotid gland may spread to the cervical lymph nodes. The superior portion of the parotid gland is near the external auditory canal of the ear, not the eustachian tube. In addition, because the parotid gland is near the skin surface, primary tumors of the parotid are typically palpable.

(Choice E) Cancer of the thyroid gland may spread to the cervical lymph nodes. However, it is very rare to have squamous cell carcinoma in the thyroid, and enlargement of the thyroid gland would not block the eustachian tube.

Educational objective:
The eustachian tube connects the middle ear to the nasopharynx. Cancer located in the nasopharynx can lead to obstruction of the eustachian tube, causing a middle ear effusion.

Anatomy	Ear, Nose & Throat (ENT)	Head and neck cancers
Subject	System	Topic

Copyright © UWorld. All rights reserved.

A 6-year-old asthmatic has the finding shown in the image below on routine examination.

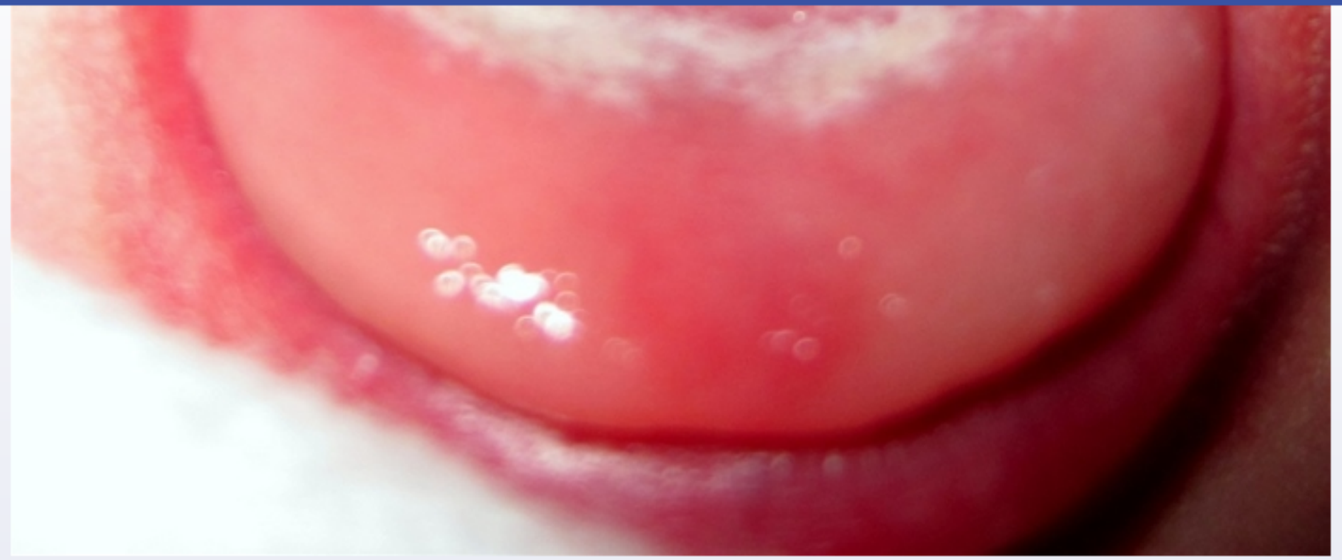

Which of the following is the most appropriate pharmacotherapy for the lesions on this patient's oral mucosa?

- A. Acyclovir
- B. Amphotericin-B
- C. Griseofulvin
- D. Nystatin
- E. Penicillin
- F. Terbinafine

Submit

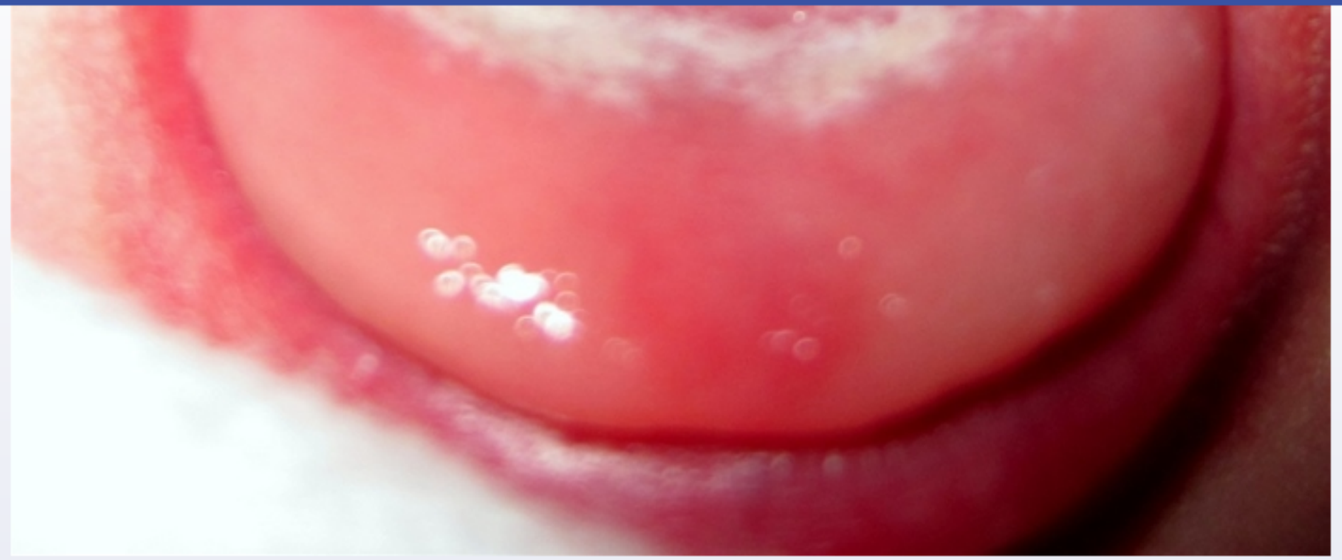

Which of the following is the most appropriate pharmacotherapy for the lesions on this patient's oral mucosa?

- A. Acyclovir (1%)
- B. Amphotericin-B (12%)
- C. Griseofulvin (4%)
- ✓ D. Nystatin (77%)
- E. Penicillin (0%)
- F. Terbinafine (2%)

Omitted
Correct answer

77%
Answered correctly

06 secs
Time Spent

05/20/2020
Last Updated

The thick white patches seen on this patient's tongue are indicative of oral thrush (oropharyngeal candidiasis). Thrush is a common variant of localized infection with *Candida* fungi. Oral thrush is common in young infants due to immaturity of the newborn immune system. In older children and adults, it is associated with immunosuppression and frequently occurs in patients with HIV infection, diabetes mellitus, and cancer. Asthma patients who take oral or inhaled steroids are also at risk for candidiasis. Systemic antibiotic therapy and dentures are other predisposing factors.

In immunocompetent patients, localized candidiasis is treated with topical antifungal medications. Nystatin is a polyene antifungal with a mechanism of action similar to amphotericin B. It binds to ergosterol molecules in the fungal cell membrane, causing pores and leakage of fungal cell contents. Nystatin is not absorbed from the gastrointestinal tract. It is administered as an oral agent ("swish and swallow") for oropharyngeal candidiasis.

(Choice A) Acyclovir is an antiviral drug effective against herpes simplex virus (1 and 2) and varicella zoster virus. It is a nucleoside analog that is converted into acyclo-GTP in infected cells, which inhibits viral DNA polymerase.

(Choice B) Amphotericin B is a polyene antifungal similar to nystatin used for systemic mycoses. It is administered intravenously and never used for simple mucocutaneous infections due to many toxic side effects.

(Choice C) Griseofulvin inhibits fungal cell mitosis at metaphase. It is indicated for the treatment of dermatophytoses, not candidiasis.

(Choice E) Penicillins are β-lactam antibiotics that inhibit the formation of peptidoglycan cross-links in bacterial cell walls.

(Choice F) Terbinafine is an allylamine antifungal that accumulates in the skin, nails, and adipose tissue. It is used to treat dermatophytosis (onychomycoses), not candidiasis.

Educational objective:
Nystatin is a polyene antifungal and the drug of choice for oropharyngeal candidiasis in patients without advanced immunodeficiency. It acts by binding to ergosterol in the fungal cell membrane, causing the formation of pores and leakage of fungal cell contents. Nystatin is not absorbed from the gastrointestinal tract and is administered as an oral "swish and swallow" agent.

Pharmacology	Ear, Nose & Throat (ENT)	Mucocutaneous candidiasis
Subject	System	Topic

A 42-year-old woman comes to the office to discuss dizziness. She has a 6-month history of episodic bouts of a "spinning sensation" associated with nausea and ringing in her left ear. The patient also has difficulty hearing while holding her phone to the left ear, although hearing in her right ear is normal. The dizziness improves spontaneously and she feels "fine" between episodes. Past medical history is notable for hypothyroidism, for which she is on thyroid replacement therapy, and endometriosis, which led to a hysterectomy at age 38. The patient works as a supermarket manager. She does not use tobacco or drink alcohol. The patient's condition is most likely the result of which of the following?

A. Demyelinating process in the central nervous system

B. Increased volume of endolymph in the inner ear

C. Inflammation of the vestibular labyrinth

D. Mass lesion at the cerebellopontine angle

E. Sclerosis of the ossicles

Submit

A 42-year-old woman comes to the office to discuss dizziness. She has a 6-month history of episodic bouts of a "spinning sensation" associated with nausea and ringing in her left ear. The patient also has difficulty hearing while holding her phone to the left ear, although hearing in her right ear is normal. The dizziness improves spontaneously and she feels "fine" between episodes. Past medical history is notable for hypothyroidism, for which she is on thyroid replacement therapy, and endometriosis, which led to a hysterectomy at age 38. The patient works as a supermarket manager. She does not use tobacco or drink alcohol. The patient's condition is most likely the result of which of the following?

A. Demyelinating process in the central nervous system (6%)
✓ B. Increased volume of endolymph in the inner ear (54%)
C. Inflammation of the vestibular labyrinth (18%)
D. Mass lesion at the cerebellopontine angle (16%)
E. Sclerosis of the ossicles (4%)

Omitted
Correct answer
B

54%
Answered correctly

01 sec
Time Spent

04/25/2020
Last Updated

Explanation

Common causes of vertigo		
	Cause	Features

Common causes of vertigo

	Cause	Features
Ménière disease	• Increased pressure & volume of endolymph	• Recurrent vertigo • Ear fullness/pain • Unilateral **hearing loss & tinnitus**
BPPV	• Otoliths in semicircular canals	• Brief episodes brought on by **head movement** • No auditory symptoms
Vestibular neuritis (labyrinthitis)	• Inflammation of vestibular nerve (viral or postviral)	• **Single episode** that can last days • Severe vertigo but no hearing loss

BPPV = benign paroxysmal positional vertigo.

©UWorld

This patient has **Ménière disease**, a disorder of the inner ear characterized by increased volume and pressure of endolymph (**endolymphatic hydrops**) that is thought to be due to defective resorption of endolymph. The resultant distension of the endolymphatic system causes damage to the vestibular and cochlear components of the inner ear. Ménière disease is characterized by the following triad:

1. Low-frequency **tinnitus**, or ringing, in the affected ear, often accompanied by a feeling of fullness
2. **Vertigo**, the subjective sensation of spinning or motion in the absence of actual motion; commonly associated with lightheadedness, nausea, and vomiting
3. **Sensorineural hearing loss**, which is variable in severity but usually worsens over time

(Choice A) Multiple sclerosis (MS) is characterized by patchy demyelination in the central nervous system that varies over time. The presentation

©UWorld

This patient has **Ménière disease**, a disorder of the inner ear characterized by increased volume and pressure of endolymph (**endolymphatic hydrops**) that is thought to be due to defective resorption of endolymph. The resultant distension of the endolymphatic system causes damage to the vestibular and cochlear components of the inner ear. Ménière disease is characterized by the following triad:

1. Low-frequency **tinnitus**, or ringing, in the affected ear, often accompanied by a feeling of fullness
2. **Vertigo**, the subjective sensation of spinning or motion in the absence of actual motion; commonly associated with lightheadedness, nausea, and vomiting
3. **Sensorineural hearing loss**, which is variable in severity but usually worsens over time

(Choice A) Multiple sclerosis (MS) is characterized by patchy demyelination in the central nervous system that varies over time. The presentation of MS is highly variable and may resemble Ménière disease, but most patients will have additional, extra-auditory symptoms (eg, visual symptoms, sensory disruptions).

(Choice C) Labyrinthitis is inflammation of the vestibular nerve that causes acute-onset vertigo, nausea, and vomiting. It usually occurs in a single episode following a viral syndrome.

(Choice D) A mass lesion at the cerebellopontine angle is most commonly an acoustic neuroma (schwannoma of CN VIII). An acoustic neuroma could cause sensorineural hearing loss, vertigo, and tinnitus, but symptoms would be persistent and progressive rather than episodic.

(Choice E) Otosclerosis is an inherited condition seen in middle age. Patients present with conductive hearing loss due to bony overgrowth of the footplate of the stapes. Vertigo does not occur.

Educational objective:
Ménière disease is characterized by tinnitus, vertigo, and sensorineural hearing loss. Its pathogenesis is related to an increased volume and pressure of endolymph in the vestibular apparatus.

References

- Endolymphatic hydrops: pathophysiology and experimental models.

Pathophysiology Ear, Nose & Throat (ENT) Meniere disease

A 48-year-old woman comes to the office due to an intermittent ear discharge over the last 2 years. She has also noticed decreased hearing in the right ear recently. Past medical history is significant for obesity, hyperlipidemia, seasonal allergies, and diet-controlled diabetes mellitus. Otoscopy shows a small perforation in the right tympanic membrane and a pearly mass behind the membrane. Conduction hearing loss is noted in the right ear. The remainder of the ear, nose, and throat examination is normal. Which of the following is the most likely cause of this patient's aural mass?

A. Cholesterol and lipid accumulation

B. Facial nerve neuroma

C. Malignant squamous cell neoplasm

D. Noncaseating granuloma

E. Squamous cell debris

Submit

A 48-year-old woman comes to the office due to an intermittent ear discharge over the last 2 years. She has also noticed decreased hearing in the right ear recently. Past medical history is significant for obesity, hyperlipidemia, seasonal allergies, and diet-controlled diabetes mellitus. Otoscopy shows a small perforation in the right tympanic membrane and a pearly mass behind the membrane. Conduction hearing loss is noted in the right ear. The remainder of the ear, nose, and throat examination is normal. Which of the following is the most likely cause of this patient's aural mass?

- A. Cholesterol and lipid accumulation (39%)
- B. Facial nerve neuroma (10%)
- C. Malignant squamous cell neoplasm (6%)
- D. Noncaseating granuloma (5%)
- ✓ E. Squamous cell debris (37%)

Omitted
Correct answer
E

37%
Answered correctly

02 secs
Time Spent

03/01/2020
Last Updated

Explanation

Cholesteatomas are collections of squamous cell debris that form a round, **pearly mass** behind the tympanic membrane in the middle ear. They can occur congenitally or may develop in adults as either an acquired primary lesion or secondary to infection, trauma, or surgery of the middle ear. Primary cholesteatomas are a result of chronic negative pressure in the middle ear causing retraction pockets in the tympanic membrane that become cystic; as the **squamous cell debris** accumulates, a cholesteatoma is formed. Secondary cholesteatomas occur after squamous epithelium migrates to or is implanted in the middle ear ("skin in the wrong place").

Explanation

Cholesteatomas are collections of squamous cell debris that form a round, **pearly mass** behind the tympanic membrane in the middle ear. They can occur congenitally or may develop in adults as either an acquired primary lesion or secondary to infection, trauma, or surgery of the middle ear. Primary cholesteatomas are a result of chronic negative pressure in the middle ear causing retraction pockets in the tympanic membrane that become cystic; as the **squamous cell debris** accumulates, a cholesteatoma is formed. Secondary cholesteatomas occur after squamous epithelium migrates to or is implanted in the middle ear ("skin in the wrong place").

Cholesteatomas most commonly cause painless otorrhea. They also can produce lytic enzymes and are often discovered when they erode through the auditory ossicles, causing conductive **hearing loss**. If a mass grows sufficiently large, it can erode into the vestibular apparatus or facial nerve, causing vertigo or facial palsies.

(Choice A) Cholesterol granulomas can form in the middle ear after hemorrhage but are much less common than cholesteatomas. They appear as bluish-black gelatinous material behind the tympanic membrane. Despite what the name implies, cholesteatomas do not contain any lipid or cholesterol components.

(Choice B) A facial nerve neuroma can grow in the middle ear as the facial nerve courses through this territory. However, it would present with unilateral facial paralysis.

(Choice C) Squamous cell carcinoma is the most common malignant tumor of the ear canal. It typically appears as an ulcerated plaque or nodule. The most common symptom is local or regional pain.

(Choice D) Granulomatous disease of the ear can occur but is uncommon and usually develops in conjunction with a systemic disease, such as sarcoidosis, granulomatosis with polyangiitis, or Langerhans cell histiocytosis.

Educational objective:
Cholesteatomas are collections of squamous cell debris that form a mass behind the tympanic membrane. Cholesteatomas can be congenital or may occur as an acquired primary lesion or following infection, trauma, or surgery of the middle ear. They can cause hearing loss due to erosion into auditory ossicles.

References

- Updates and knowledge gaps in cholesteatoma research.

A 4-hour-old girl with a cleft lip is breastfeeding without difficulty. The infant was born vaginally after an uncomplicated pregnancy and delivery. Routine antenatal sonography at 20 weeks gestation showed no abnormalities. Physical examination shows an intact palate and a unilateral cleft lip on the left side. No other abnormalities are seen. This child's cleft lip resulted from failure of which of the following intrauterine processes?

A. Fusion of the 2 medial nasal prominences

B. Fusion of the maxillary prominence and intermaxillary segment

C. Fusion of the palatal processes

D. Hyperplasia of the frontonasal prominence

E. Hypoplasia of the mandibular prominence

Submit

A 4-hour-old girl with a cleft lip is breastfeeding without difficulty. The infant was born vaginally after an uncomplicated pregnancy and delivery. Routine antenatal sonography at 20 weeks gestation showed no abnormalities. Physical examination shows an intact palate and a unilateral cleft lip on the left side. No other abnormalities are seen. This child's cleft lip resulted from failure of which of the following intrauterine processes?

- A. Fusion of the 2 medial nasal prominences (33%)
- ✓ B. Fusion of the maxillary prominence and intermaxillary segment (59%)
- C. Fusion of the palatal processes (5%)
- D. Hyperplasia of the frontonasal prominence (1%)
- E. Hypoplasia of the mandibular prominence (1%)

Omitted
Correct answer
B

59%
Answered correctly

02 secs
Time Spent

04/04/2020
Last Updated

Explanation

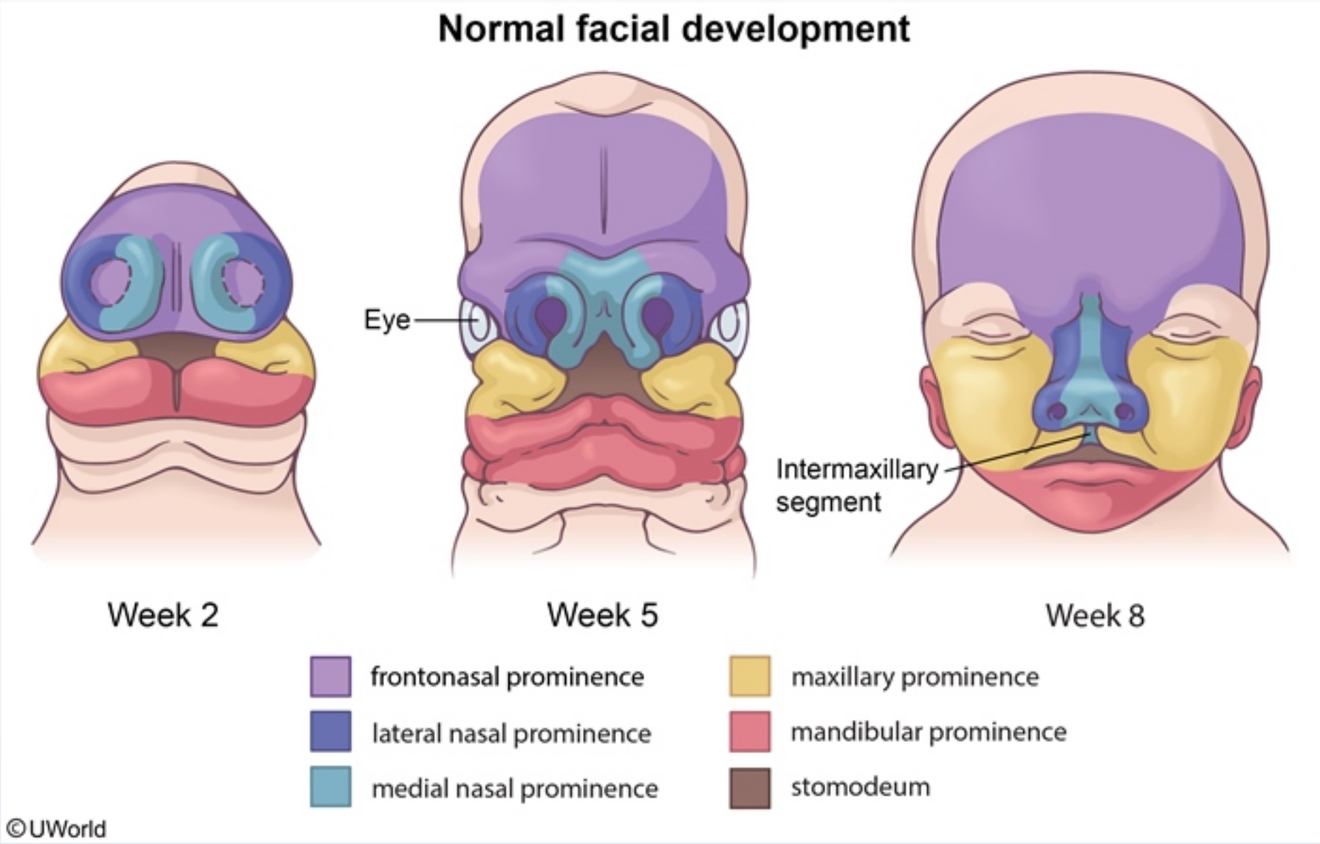

The lip and palate form during the **fifth-sixth week** of embryonic development through a series of fusions:

1. The first pharyngeal arch splits into the upper maxillary prominence and the lower mandibular prominence.
2. Fusion of the 2 medial nasal prominences forms the midline **intermaxillary segment**. The intermaxillary segment will become the philtrum of the upper lip, the 4 medial maxillary teeth, and the primary palate.
3. The left and right maxillary prominences then fuse with the midline intermaxillary segment to form the **upper lip** and **primary palate**. If one of the maxillary prominences fails to fuse with the intermaxillary segment, a unilateral cleft lip results. If both maxillary prominences fail to

The lip and palate form during the **fifth-sixth week** of embryonic development through a series of fusions:

1. The first pharyngeal arch splits into the upper maxillary prominence and the lower mandibular prominence.
2. Fusion of the 2 medial nasal prominences forms the midline **intermaxillary segment**. The intermaxillary segment will become the philtrum of the upper lip, the 4 medial maxillary teeth, and the primary palate.
3. The left and right maxillary prominences then fuse with the midline intermaxillary segment to form the **upper lip** and **primary palate**. If one of the maxillary prominences fails to fuse with the intermaxillary segment, a unilateral cleft lip results. If both maxillary prominences fail to fuse with the intermaxillary segment, bilateral cleft lip results.

(Choice A) Failure of the medial nasal prominence to fuse and form the intermaxillary segment is associated with severe midline defects, such as holoprosencephaly.

(Choice C) During the seventh-eighth week of embryonic development, the maxillary prominences give rise to palatine shelves. The thin sheets of tissue that comprise the palatine shelves grow medially and fuse into the **secondary palate**. Fusion of the secondary palate with the posterior aspect of the primary palate forms the complete palate. Failure of any of these processes can lead to **cleft palate**. The presence of a cleft lip increases the risk of cleft palate, but either can occur in isolation.

(Choice D) The orbits normally arise from the sides of the face and rotate medially. However, excessive tissue from the frontal nasal prominence could result in orbital hypertelorism (wide-set eyes) in addition to a broad forehead and wide nasal bridge.

(Choice E) Micrognathia is characterized by hypoplasia of the mandibular prominence. In Pierre-Robin sequence, the severe micrognathia results in posterior displacement of the tongue (glossoptosis) and prevents fusion of the secondary palate (cleft palate).

Educational objective:
Cleft lip results when the maxillary prominence fails to fuse with the intermaxillary segment during the fifth-sixth week of embryonic development. Cleft palate occurs when the palatine shelves fail to fuse with one another or with the primary palate. Cleft lip and palate can occur together or in isolation.

References

- Cleft lip and palate: understanding genetic and environmental influences.
- Cleft lip and palate: an evidence-based review.

1
2
3
4
5
6
7
8
9
10
11
12
13
14
15
16
17
18
19
20
21
22
23
24

The lip and palate form during the **fifth-sixth week** of embryonic development through a series of fusions:

Exhibit Display

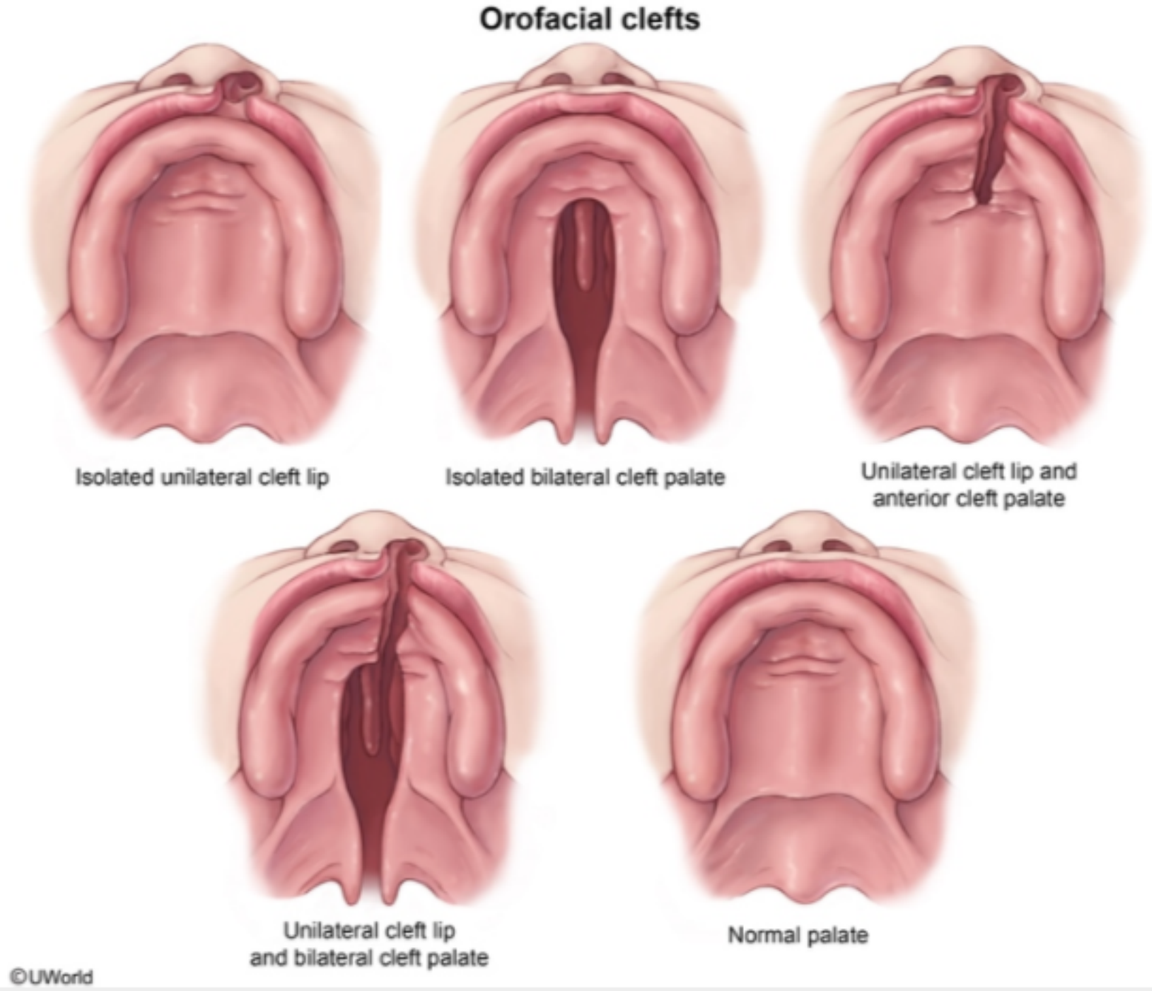

Zoom In | Zoom Out | Reset | Add To New Card | Existing Card

- Cleft lip and palate: an evidence-based review.

1
2
3
4
5
6
7
8
9
10
11
12
13
14
15
16
17
18
19
20
21
22
23
24

The lip and palate form during the **fifth-sixth week** of embryonic development through a series of fusions:

Exhibit Display

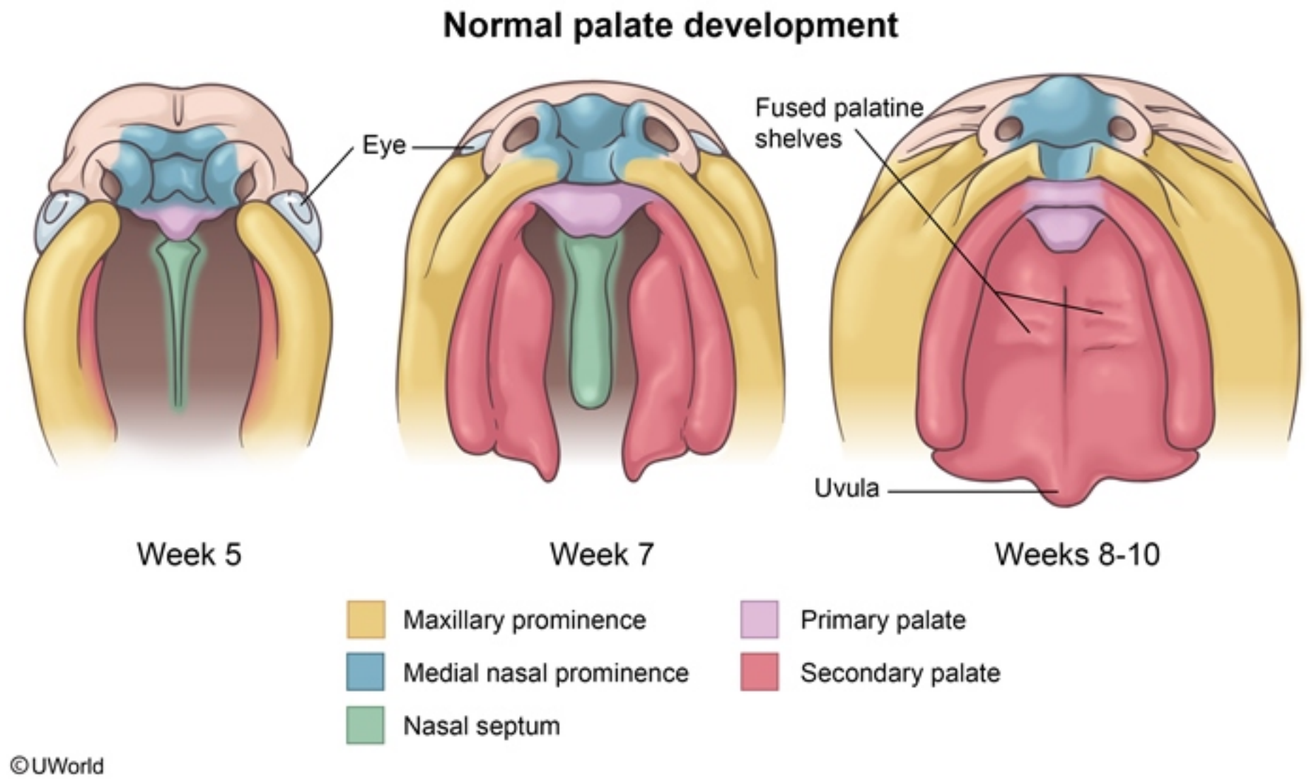

Zoom In | Zoom Out | Reset | Add To New Card | Existing Card

- Cleft lip and palate: an evidence-based review.

The lip and palate form during the **fifth-sixth week** of embryonic development through a series of fusions:

Exhibit Display

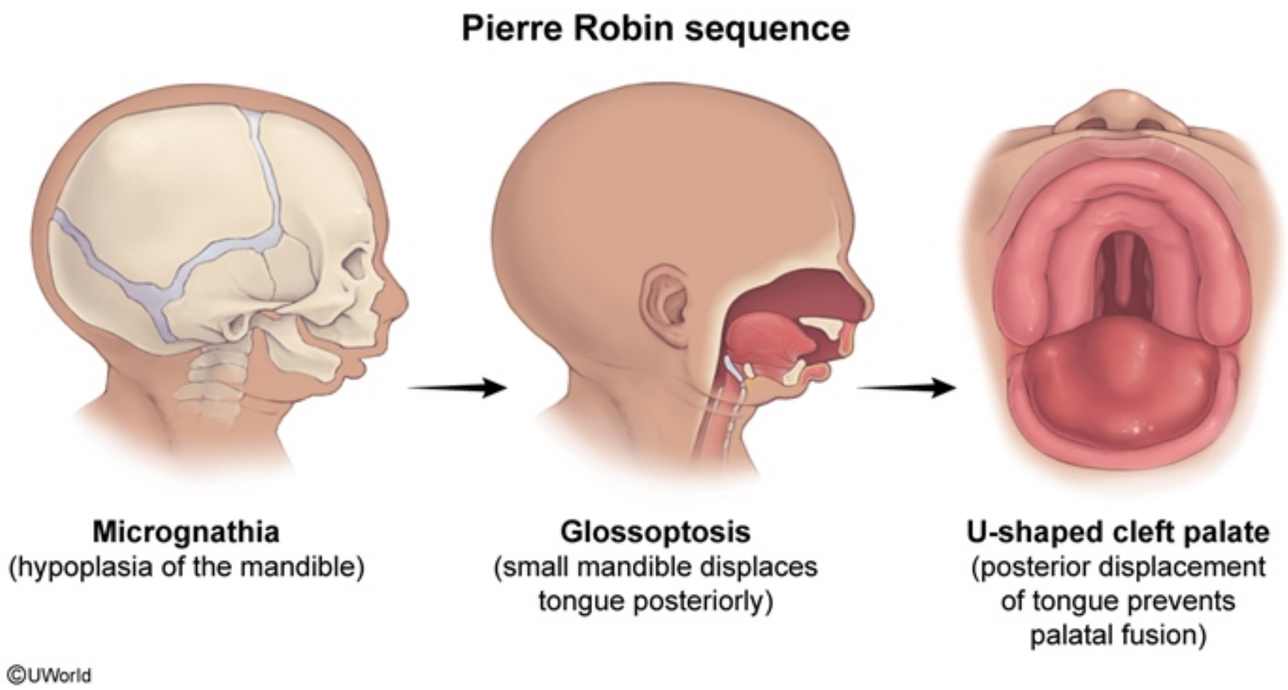

Zoom In | Zoom Out | Reset | Add To New Card | Existing Card

- Cleft lip and palate: an evidence-based review.

A 35-year-old man comes to the physician because of a 2-week history of nasal congestion. He has used a topical decongestant every few hours since his symptoms began. He experienced relief for almost 1 week, but then his nasal congestion returned. The patient has a history of allergic rhinitis and has had episodes of rhinorrhea in the past, but none of them lasted longer than a few days. He denies fever, throat pain, headaches, cough, and lymph node enlargement. Aside from his allergic rhinitis, the patient has no other medical problems. Physical examination shows nasal mucosa that appears edematous and red with a few areas of punctate bleeding. The remainder of the examination reveals no abnormalities. Which of the following is the most appropriate next step in the management of this patient?

- A. Stop the decongestant
- B. Switch to ephedrine
- C. Add oral corticosteroids
- D. Add antihistamines
- E. Start antibiotics

Submit

A 35-year-old man comes to the physician because of a 2-week history of nasal congestion. He has used a topical decongestant every few hours since his symptoms began. He experienced relief for almost 1 week, but then his nasal congestion returned. The patient has a history of allergic rhinitis and has had episodes of rhinorrhea in the past, but none of them lasted longer than a few days. He denies fever, throat pain, headaches, cough, and lymph node enlargement. Aside from his allergic rhinitis, the patient has no other medical problems. Physical examination shows nasal mucosa that appears edematous and red with a few areas of punctate bleeding. The remainder of the examination reveals no abnormalities. Which of the following is the most appropriate next step in the management of this patient?

- ✓ A. Stop the decongestant (67%)
- B. Switch to ephedrine (8%)
- C. Add oral corticosteroids (5%)
- D. Add antihistamines (15%)
- E. Start antibiotics (2%)

Omitted
Correct answer
A

67%
Answered correctly

02 secs
Time Spent

05/25/2020
Last Updated

Explanation

Vasoconstriction by α-adrenergic agonists is prominent in the vessels of the nasal mucosa, making these medications effective decongestants. Phenylephrine, xylometazoline, and oxymetazoline are used as topical preparations for the treatment of allergic rhinitis and common cold associated congestion and rhinitis.

These medications, however, are characterized by rapidly declining effect after a few days of use. This phenomenon is called tachyphylaxis. It

Vasoconstriction by α-adrenergic agonists is prominent in the vessels of the nasal mucosa, making these medications effective decongestants. Phenylephrine, xylometazoline, and oxymetazoline are used as topical preparations for the treatment of allergic rhinitis and common cold associated congestion and rhinitis.

These medications, however, are characterized by rapidly declining effect after a few days of use. This phenomenon is called tachyphylaxis. It occurs because of decreased production of endogenous norepinephrine from the nerve terminals due to a negative feedback mechanism, resulting in relative vasodilation (ie, removal of normal vasoconstrictive tone) and subsequent edema and congestion. This leads to exacerbation of the nasal congestion symptoms. Rebound rhinorrhea (ie, rhinitis medicamentosa) is described as nasal congestion without cough, sneezing, or postnasal drip. Rhinorrhea may or may not be present (note the paradox in naming). Rebound rhinorrhea is associated with the use of topical decongestants for ≥ 3 days. The use of adrenergic agonists should be stopped to allow the restoration of normal norepinephrine feedback pathways.

Another medication associated with the phenomenon of tachyphylaxis is nitroglycerine. The decrease in its effect is explained by the diminished release of NO from the target cells. Drug-free intervals of 8–10 hours should be maintained during the use of nitroglycerine to prevent tachyphylaxis.

(Choice B) Ephedrine is an indirect-acting adrenergic agonist used as a decongestant. Like the other adrenergic medications, it causes tachyphylaxis after a few days of treatment. A switch to ephedrine would not improve this patient's rebound rhinorrhea.

(Choice C) This patient has been excessively using a decongestant; if he discontinues it and experiences excessive withdrawal symptoms, a short-term course of topical corticosteroids can be considered for symptom control. However, oral corticosteroids would not be indicated.

(Choice D) Antihistamines are used for the treatment of allergic rhinitis, but they are not effective in treating rebound rhinorrhea.

(Choice E) Antibiotics are effective in the treatment of certain bacterial infections. They are not used in the treatment of rebound rhinorrhea.

Educational objective:
Topical preparations of α-adrenergic agonists cause vasoconstriction of the nasal mucosa vessels and are used as decongestants. Overuse of these drugs causes negative feedback, resulting in decreased norepinephrine synthesis and release from nerve endings, which diminishes their effect (ie, tachyphylaxis).

References

postnasal drip. Rhinorrhea may or may not be present (note the paradox in naming). Rebound rhinorrhea is associated with the use of topical decongestants for ≥ 3 days. The use of adrenergic agonists should be stopped to allow the restoration of normal norepinephrine feedback pathways.

Another medication associated with the phenomenon of tachyphylaxis is nitroglycerine. The decrease in its effect is explained by the diminished release of NO from the target cells. Drug-free intervals of 8–10 hours should be maintained during the use of nitroglycerine to prevent tachyphylaxis.

(Choice B) Ephedrine is an indirect-acting adrenergic agonist used as a decongestant. Like the other adrenergic medications, it causes tachyphylaxis after a few days of treatment. A switch to ephedrine would not improve this patient's rebound rhinorrhea.

(Choice C) This patient has been excessively using a decongestant; if he discontinues it and experiences excessive withdrawal symptoms, a short-term course of topical corticosteroids can be considered for symptom control. However, oral corticosteroids would not be indicated.

(Choice D) Antihistamines are used for the treatment of allergic rhinitis, but they are not effective in treating rebound rhinorrhea.

(Choice E) Antibiotics are effective in the treatment of certain bacterial infections. They are not used in the treatment of rebound rhinorrhea.

Educational objective:
Topical preparations of α-adrenergic agonists cause vasoconstriction of the nasal mucosa vessels and are used as decongestants. Overuse of these drugs causes negative feedback, resulting in decreased norepinephrine synthesis and release from nerve endings, which diminishes their effect (ie, tachyphylaxis).

References

- Rhinitis medicamentosa.
- Diagnosing rhinitis: allergic vs. nonallergic.

Pharmacology	Ear, Nose & Throat (ENT)	Nonallergic rhinitis
Subject	System	Topic

Copyright © UWorld. All rights reserved.

A 3-year-old boy is brought to the office due to a 1-day history of fever and irritability. The mother states that the boy has been tugging at his right ear. The patient has had 2 previous episodes of acute otitis media. Temperature is 38.1 C (100.6 F). Otoscopic examination shows a perforated right tympanic membrane with erythema and purulent exudate. Cultures from the exudate yield small, oxidase-positive, gram-negative coccobacilli that grow on factor X– and factor V–supplemented media, consistent with *Haemophilus influenzae*. The patient's immunizations are up to date. Which of the following best explains this patient's susceptibility to the pathogen causing his current infection?

A. No vaccine is effective against *H influenzae*

B. The patient has defective cell-mediated immunity

C. The patient has defective neutrophil function

D. The strain responsible for this patient's disease does not produce a capsule

E. The strain responsible for this patient's disease produces exotoxin

Submit

A 3-year-old boy is brought to the office due to a 1-day history of fever and irritability. The mother states that the boy has been tugging at his right ear. The patient has had 2 previous episodes of acute otitis media. Temperature is 38.1 C (100.6 F). Otoscopic examination shows a perforated right tympanic membrane with erythema and purulent exudate. Cultures from the exudate yield small, oxidase-positive, gram-negative coccobacilli that grow on factor X– and factor V–supplemented media, consistent with *Haemophilus influenzae*. The patient's immunizations are up to date. Which of the following best explains this patient's susceptibility to the pathogen causing his current infection?

- A. No vaccine is effective against *H influenzae* (2%)
- B. The patient has defective cell-mediated immunity (16%)
- C. The patient has defective neutrophil function (11%)
- ✓ D. The strain responsible for this patient's disease does not produce a capsule (65%)
- E. The strain responsible for this patient's disease produces exotoxin (4%)

Omitted
Correct answer
D

65%
Answered correctly

02 secs
Time Spent

01/19/2020
Last Updated

Explanation

This patient with fever and an inflamed, perforated tympanic membrane with purulent otorrhea has **acute otitis media**. Middle ear infections occur most commonly in young children (age 6 months to 2 years) and are typically due to *Streptococcus pneumoniae* or ***Haemophilus influenzae***.

H influenzae is a small, oxidase-positive, gram-negative coccobacillus classified by the antigens in its polysaccharide **capsule**. Strains of *H influenzae* that do not produce a capsule are referred to as **nontypeable**. These nontypeable strains are part of the normal upper respiratory tract

Explanation

This patient with fever and an inflamed, perforated tympanic membrane with purulent otorrhea has **acute otitis media**. Middle ear infections occur most commonly in young children (age 6 months to 2 years) and are typically due to *Streptococcus pneumoniae* or ***Haemophilus influenzae***.

H influenzae is a small, oxidase-positive, gram-negative coccobacillus classified by the antigens in its polysaccharide **capsule**. Strains of *H influenzae* that do not produce a capsule are referred to as **nontypeable**. These nontypeable strains are part of the normal upper respiratory tract flora but can also cause acute otitis media, sinusitis, and bronchitis. Most *H influenzae* strains isolated from middle ear aspirates of children with acute otitis media are nontypeable.

Vaccination against *H influenzae* is with the protein-conjugated **Hib vaccine**, which confers immunity only to the more invasive **type b** strain **(Choice A)**. The vaccine is recommended in all children beginning at age 2 months to prevent Hib-associated bacteremia, pneumonia, epiglottitis, and meningitis.

(Choice B) The Hib vaccine contains capsular polysaccharide components to induce anticapsular antibodies (humoral immune response). Because the antibody response is weak in children, the vaccine is also conjugated with toxoid protein, which stimulates a helper T-cell response to help activate B-cell antibody formation. A cell-mediated cytotoxic T-cell response is not induced.

(Choice C) Poor neutrophil function or a low neutrophil count predisposes to bacterial disease. However, neutrophil dysfunction (eg, chronic granulomatous disease, Chédiak-Higashi syndrome) typically presents with recurrent, severe bacterial infections such as pneumonia and abscesses. Ear infections due to *H influenzae* infection despite immunization with the Hib vaccine are more likely due to infection with a nontypeable strain than defective neutrophils.

(Choice E) Exotoxins are secreted by certain bacteria (eg, *Clostridium botulinum*, *Corynebacterium diphtheriae*) to promote cell death but are not generally produced by any strain of *H influenzae*. The Hib vaccine is directed against capsular polysaccharide, not toxin.

Educational objective:
Nontypeable strains of *Haemophilus influenzae* are part of the normal upper respiratory tract flora and are a common cause of acute otitis media, sinusitis, and bronchitis. Because nontypeable strains do not form a polysaccharide capsule, immunity is not conferred by vaccination with the *H influenzae* type b vaccine.

1
2
3
4
5
6
7
8
9
10
11
12
13
14
15
16
17
18
19
20
21
22
23
24

Explanation

Exhibit Display



Zoom In | Zoom Out | Reset | Add To New Card | Existing Card

1
2
3
4
5
6
7
8
9
10
11
12
13
14
15
16
17
18
19
20
21
22
23
24

Explanation

Exhibit Display

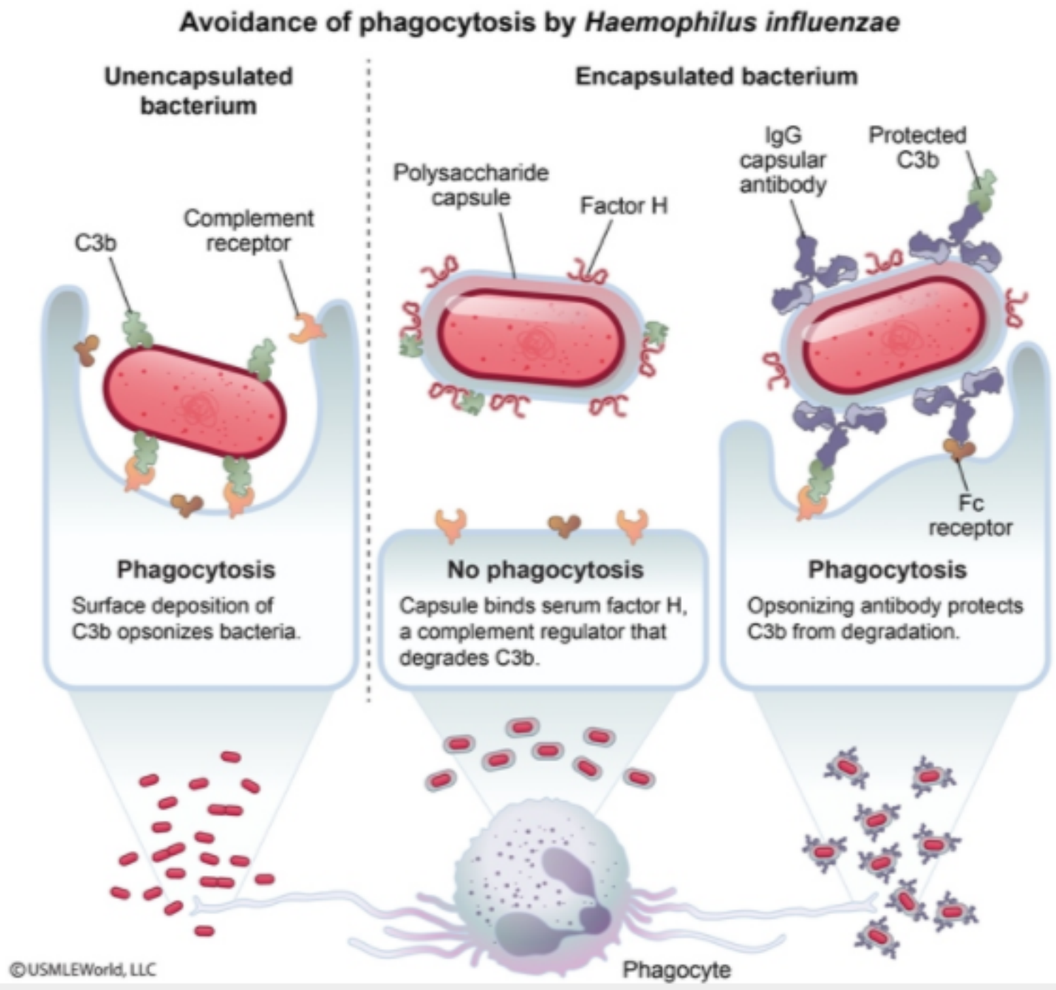

Zoom In | Zoom Out | Reset | Add To New Card | Existing Card

Vaccination against *H influenzae* is with the protein-conjugated **Hib vaccine**, which confers immunity only to the more invasive **type b** strain **(Choice A)**. The vaccine is recommended in all children beginning at age 2 months to prevent Hib-associated bacteremia, pneumonia, epiglottitis, and meningitis.

(Choice B) The Hib vaccine contains capsular polysaccharide components to induce anticapsular antibodies (humoral immune response). Because the antibody response is weak in children, the vaccine is also conjugated with toxoid protein, which stimulates a helper T-cell response to help activate B-cell antibody formation. A cell-mediated cytotoxic T-cell response is not induced.

(Choice C) Poor neutrophil function or a low neutrophil count predisposes to bacterial disease. However, neutrophil dysfunction (eg, chronic granulomatous disease, Chédiak-Higashi syndrome) typically presents with recurrent, severe bacterial infections such as pneumonia and abscesses. Ear infections due to *H influenzae* infection despite immunization with the Hib vaccine are more likely due to infection with a nontypeable strain than defective neutrophils.

(Choice E) Exotoxins are secreted by certain bacteria (eg, *Clostridium botulinum*, *Corynebacterium diphtheriae*) to promote cell death but are not generally produced by any strain of *H influenzae*. The Hib vaccine is directed against capsular polysaccharide, not toxin.

Educational objective:

Nontypeable strains of *Haemophilus influenzae* are part of the normal upper respiratory tract flora and are a common cause of acute otitis media, sinusitis, and bronchitis. Because nontypeable strains do not form a polysaccharide capsule, immunity is not conferred by vaccination with the *H influenzae* type b vaccine.

References

- Etiology of acute otitis media and serotype distribution of Streptococcus pneumoniae and Haemophilus influenzae in Chilean children <5 years of age.
- Non-capsulated and capsulated Haemophilus influenzae in children with acute otitis media in Venezuela: a prospective epidemiological study.

Microbiology	Ear, Nose & Throat (ENT)	Otitis media
Subject	System	Topic

Copyright © UWorld. All rights reserved.

A 25-year-old woman comes to the office due to right ear pain that has worsened over the past 2 months. The pain is dull and constant and waxes and wanes. It is worse when she chews hard foods such as steak or almonds. In addition to ear pain, her ear feels stuffy and has some ringing. The patient grinds her teeth at night and previously wore a dental guard, but it broke several months ago. Ear examination is normal. Which of the following nerves is most likely responsible for this patient's ear pain?

A. Glossopharyngeal

B. Hypoglossal

C. Trigeminal

D. Vagus

E. Vestibulocochlear

Submit

A 25-year-old woman comes to the office due to right ear pain that has worsened over the past 2 months. The pain is dull and constant and waxes and wanes. It is worse when she chews hard foods such as steak or almonds. In addition to ear pain, her ear feels stuffy and has some ringing. The patient grinds her teeth at night and previously wore a dental guard, but it broke several months ago. Ear examination is normal. Which of the following nerves is most likely responsible for this patient's ear pain?

- A. Glossopharyngeal (6%)
- B. Hypoglossal (0%)
- ✓ C. Trigeminal (75%)
- D. Vagus (4%)
- E. Vestibulocochlear (12%)

Omitted
Correct answer
C

75%
Answered correctly

02 secs
Time Spent

03/23/2020
Last Updated

Explanation

Mandibular division of trigeminal nerve

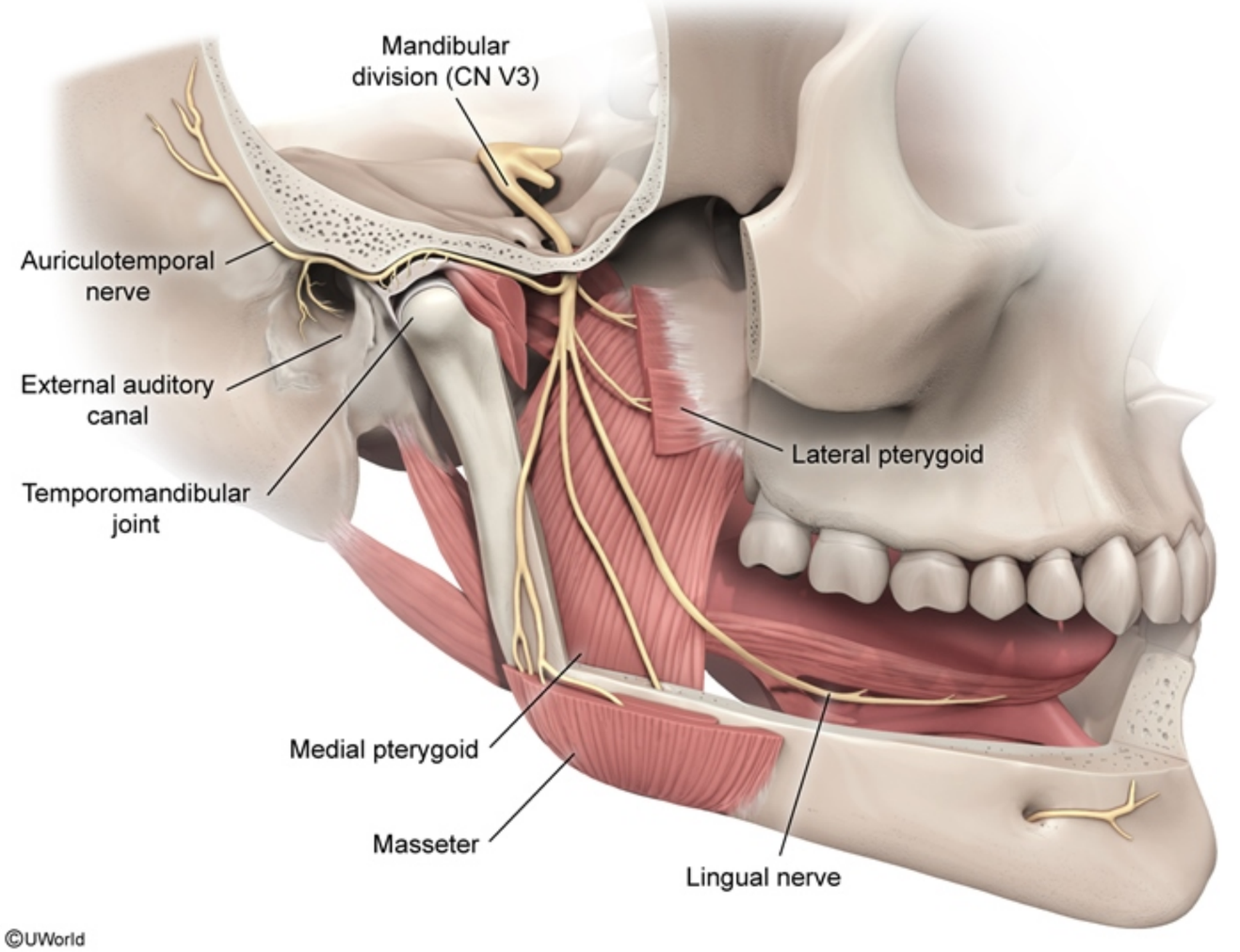

This patient's presentation is most consistent with **temporomandibular joint disorder** (TMD). The underlying etiology of TMD is multifactorial and includes temporomandibular joint derangement (eg, jaw misalignment, jaw clenching/teeth grinding, trauma) and hypersensitivity of the

©UWorld

This patient's presentation is most consistent with **temporomandibular joint disorder** (TMD). The underlying etiology of TMD is multifactorial and includes temporomandibular joint derangement (eg, jaw misalignment, jaw clenching/teeth grinding, trauma) and hypersensitivity of the mandibular nerve (CN V3). In addition to the classic symptoms of dull, waxing-and-waning face/jaw pain (worse with chewing) and clicking/popping noises with jaw movement, TMD can also present with ear-related symptoms (eg, ear pain, ear stuffiness, tinnitus).

Many of these clinical findings are due to involvement of the **mandibular nerve** (CN V3), which is the largest branch of the **trigeminal nerve**. It supplies sensation to the temporomandibular joint, floor of mouth, anterior tongue, and lower part of the face. In addition, it contributes to the sensory innervation of the **external auditory canal**; therefore, TMD can present with **ear pain** that is **referred** from the jaw joint. Ear stuffiness may be related to hypersensitivity affecting the tensor tympani. Theories regarding tinnitus in TMD include the proximity of the muscles of mastication to the ear and central connections between nerve supply of the temporomandibular joint and the areas of the brain involved in hearing.

(Choice A) The sensory component of the glossopharyngeal nerve (CN IX) carries general sensory information from the tonsils, pharynx, middle ear, and posterior third of the tongue; special sensory information (taste) from the posterior third of the tongue; and visceral sensory information from the carotid bodies and carotid sinus.

(Choice B) The hypoglossal nerve (CN XII) carries general motor efferent information to the intrinsic and extrinsic muscles of the tongue.

(Choice D) The auricular branch of the vagus nerve (CN X) conveys sensory information from the external auditory canal but is not thought to be involved in the pathogenesis of TMD.

(Choice E) The vestibulocochlear nerve (CN VIII) carries only special sensory information (auditory and balance) from the inner ear.

Educational objective:
Temporomandibular joint disorder is associated with derangement of the temporomandibular joint and hypersensitivity of the mandibular nerve (CN V3).

References

- Temporomandibular disorder: otologic implications and its relationship to sleep bruxism.
- Temporomandibular disorder: an underdiagnosed cause of headache, sinus pain, and ear pain.

A 44-year-old man comes to the office for evaluation of a neck lump. The patient first noticed the lump 6 months ago while he was shaving and says that it seems to be growing in size. He has no pain, shortness of breath, cough, hoarseness, or difficulty swallowing. The patient had Hodgkin lymphoma 20 years ago, which was successfully treated with radiation therapy to his chest and neck. Physical examination shows a firm mass in the left thyroid lobe. There is no lymphadenopathy. Serum TSH level is normal. Fine-needle aspiration biopsy reveals papillary thyroid cancer. A total thyroidectomy is performed. During an attempt to ligate the inferior thyroid artery, a nervous structure in close proximity is inadvertently damaged. Which of the following was most likely injured during the surgery?

A. Accessory nerve
B. Ansa cervicalis
C. Hypoglossal nerve
D. Phrenic nerve
E. Recurrent laryngeal nerve
F. Superior cervical ganglion
G. Superior laryngeal nerve

Submit

A 44-year-old man comes to the office for evaluation of a neck lump. The patient first noticed the lump 6 months ago while he was shaving and says that it seems to be growing in size. He has no pain, shortness of breath, cough, hoarseness, or difficulty swallowing. The patient had Hodgkin lymphoma 20 years ago, which was successfully treated with radiation therapy to his chest and neck. Physical examination shows a firm mass in the left thyroid lobe. There is no lymphadenopathy. Serum TSH level is normal. Fine-needle aspiration biopsy reveals papillary thyroid cancer. A total thyroidectomy is performed. During an attempt to ligate the inferior thyroid artery, a nervous structure in close proximity is inadvertently damaged. Which of the following was most likely injured during the surgery?

- A. Accessory nerve (0%)
- B. Ansa cervicalis (2%)
- C. Hypoglossal nerve (0%)
- D. Phrenic nerve (1%)
- ✓ E. Recurrent laryngeal nerve (81%)
- F. Superior cervical ganglion (0%)
- G. Superior laryngeal nerve (13%)

Omitted
Correct answer
E

81%
Answered correctly

01 sec
Time Spent

04/06/2020
Last Updated

Explanation

1
2
3
4
5
6
7
8
9
10
11
12
13
14
15
16
17
18
19
20
21
22
23
24

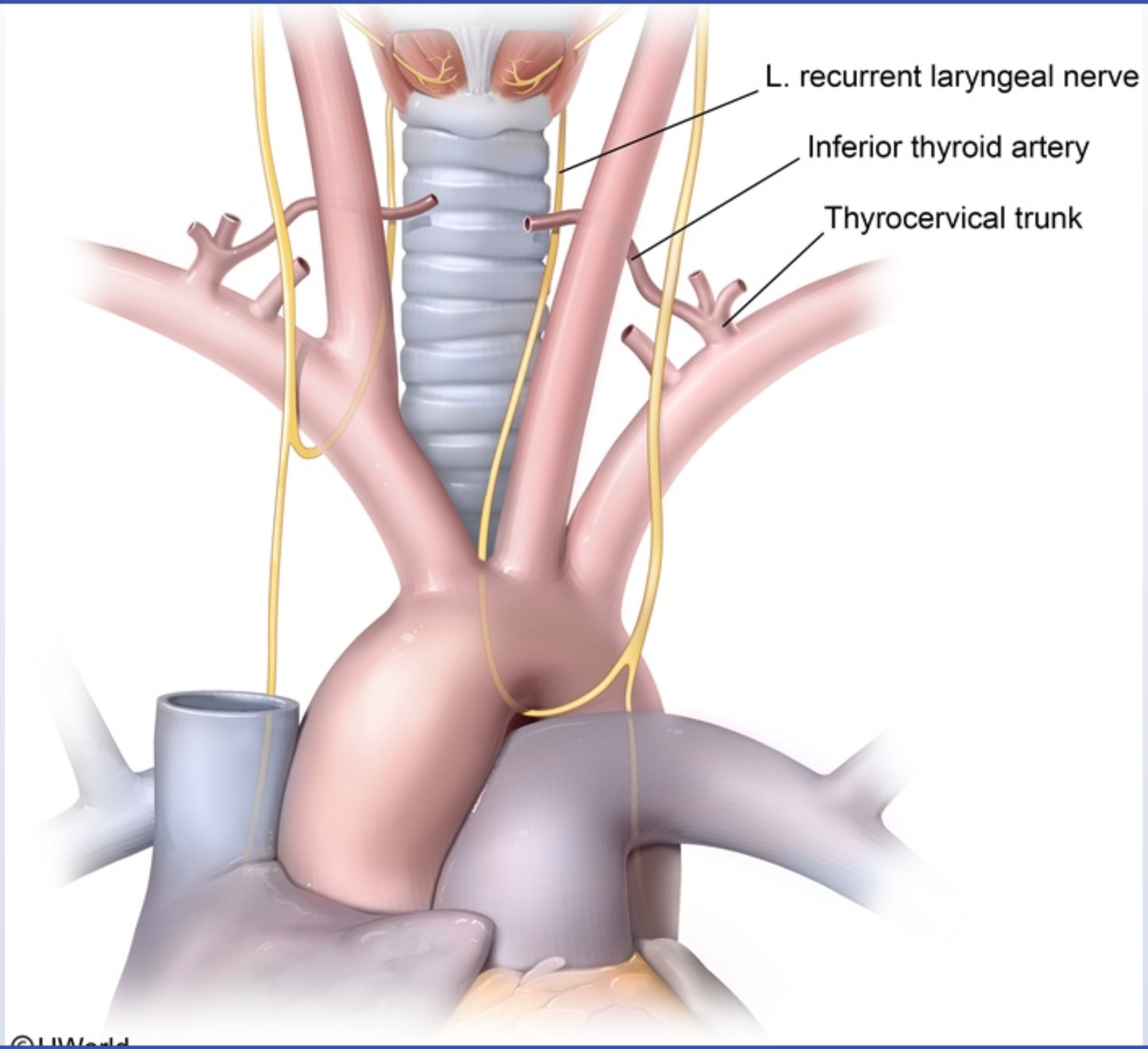

©UWorld

The **inferior thyroid artery** arises from the thyrocervical trunk, a branch of the subclavian artery. Along with the superior thyroid arteries (branches of the external carotid arteries), the inferior thyroid arteries provide blood to the thyroid gland and other structures of the anterior neck. From the thyrocervical trunk, the inferior thyroid artery courses deep to the internal jugular vein, vagus nerve, and common carotid artery before turning toward the thyroid. As it approaches the thyroid, the artery comes in **close proximity** to the **recurrent laryngeal nerve**.

The recurrent laryngeal nerve is a branch of the vagus nerve that loops below the aortic arch on the left and below the subclavian artery on the right to provide motor innervation to the intrinsic muscles of the larynx (except the cricothyroid). During **thyroid surgery**, this nerve may be **damaged** due to its proximity to the inferior thyroid artery. Unilateral nerve injury often causes **hoarseness**, whereas bilateral injury may cause inspiratory stridor and respiratory distress due to complete **vocal cord paralysis**.

(Choice A) The spinal accessory nerve (CN XI) exits the jugular foramen and courses on top of the levator scapulae muscle to innervate the sternocleidomastoid and trapezius muscles on either side.

(Choice B) The ansa cervicalis is a loop of the cervical plexus that receives contributions from C1-C3. It courses deep to the sternocleidomastoid muscle and loops around the internal jugular vein. Branches from the ansa cervicalis innervate the sternohyoid, sternothyroid, and omohyoid muscles.

(Choice C) The hypoglossal nerve (CN XII) exits the cranium through the hypoglossal canal and innervates all the muscles of the tongue except the palatoglossus.

(Choice D) The phrenic nerve arises from the C3-C5 cervical nerves and innervates the diaphragm. The most common cause of iatrogenic phrenic nerve injury is cardiothoracic surgery, in which the nerve can be damaged where it passes between the pericardium and mediastinal pleura. Manifestations include diaphragmatic paralysis (inspiratory weakness).

(Choice F) The superior cervical ganglion is part of the sympathetic nervous system. It can be injured by an expanding lung cancer at the superior pulmonary sulcus (Pancoast tumor), leading to Horner syndrome (ie, ipsilateral ptosis, miosis, and anhydrosis).

(Choice G) The superior laryngeal nerve branches off the vagus nerve high in the neck and divides into an external branch, which supplies the cricothyroid muscle, and an internal branch, which provides sensation over the supraglottic area. The external branch of this nerve may be misligated during thyroid surgery due to its proximity to the superior thyroid artery.

(Choice B) The ansa cervicalis is a loop of the cervical plexus that receives contributions from C1-C3. It courses deep to the sternocleidomastoid muscle and loops around the internal jugular vein. Branches from the ansa cervicalis innervate the sternohyoid, sternothyroid, and omohyoid muscles.

(Choice C) The hypoglossal nerve (CN XII) exits the cranium through the hypoglossal canal and innervates all the muscles of the tongue except the palatoglossus.

(Choice D) The phrenic nerve arises from the C3-C5 cervical nerves and innervates the diaphragm. The most common cause of iatrogenic phrenic nerve injury is cardiothoracic surgery, in which the nerve can be damaged where it passes between the pericardium and mediastinal pleura. Manifestations include diaphragmatic paralysis (inspiratory weakness).

(Choice F) The superior cervical ganglion is part of the sympathetic nervous system. It can be injured by an expanding lung cancer at the superior pulmonary sulcus (Pancoast tumor), leading to Horner syndrome (ie, ipsilateral ptosis, miosis, and anhydrosis).

(Choice G) The superior laryngeal nerve branches off the vagus nerve high in the neck and divides into an external branch, which supplies the cricothyroid muscle, and an internal branch, which provides sensation over the supraglottic area. The external branch of this nerve may be misligated during thyroid surgery due to its proximity to the superior thyroid artery.

Educational objective:
The recurrent laryngeal nerve travels in close proximity to the inferior thyroid artery and can be injured during thyroid surgery, resulting in vocal cord paralysis (eg, hoarseness).

References

- Anatomical relationship between recurrent laryngeal nerve and inferior thyroid artery in thyroidectomy patients.
- An applied anatomical study on the recurrent laryngeal nerve and inferior thyroid artery.

Anatomy	Ear, Nose & Throat (ENT)	Thyroid cancer
Subject	System	Topic

Copyright © UWorld. All rights reserved.

A 7-year-old boy is brought to the office for evaluation of a neck mass. A week ago, the patient was taken to an urgent care clinic for nasal congestion and sore throat. The symptoms resolved after a few days, but his parents noticed a persistent neck swelling. The patient has no prior medical conditions, and his immunizations are up to date. On physical examination, he appears well and is well nourished. Neck examination shows a mildly tender, 2-cm, midline mass that moves up when the patient swallows. Which of the following is the most likely cause of this patient's lesion?

- A. Abnormal migration of neural crest cells
- B. Cervical implantation of thymic tissue
- C. Dilation of cervical lymphatic channels
- D. Incomplete obliteration of a duct
- E. Persistence of second branchial arch structures
- F. Trapping of skin structures along embryonic fusion lines

Submit

A 7-year-old boy is brought to the office for evaluation of a neck mass. A week ago, the patient was taken to an urgent care clinic for nasal congestion and sore throat. The symptoms resolved after a few days, but his parents noticed a persistent neck swelling. The patient has no prior medical conditions, and his immunizations are up to date. On physical examination, he appears well and is well nourished. Neck examination shows a mildly tender, 2-cm, midline mass that moves up when the patient swallows. Which of the following is the most likely cause of this patient's lesion?

- A. Abnormal migration of neural crest cells (7%)
- B. Cervical implantation of thymic tissue (8%)
- C. Dilation of cervical lymphatic channels (4%)
- ✓ D. Incomplete obliteration of a duct (70%)
- E. Persistence of second branchial arch structures (7%)
- F. Trapping of skin structures along embryonic fusion lines (0%)

Omitted
Correct answer
D

70%
Answered correctly

01 sec
Time Spent

05/06/2020
Last Updated

Explanation

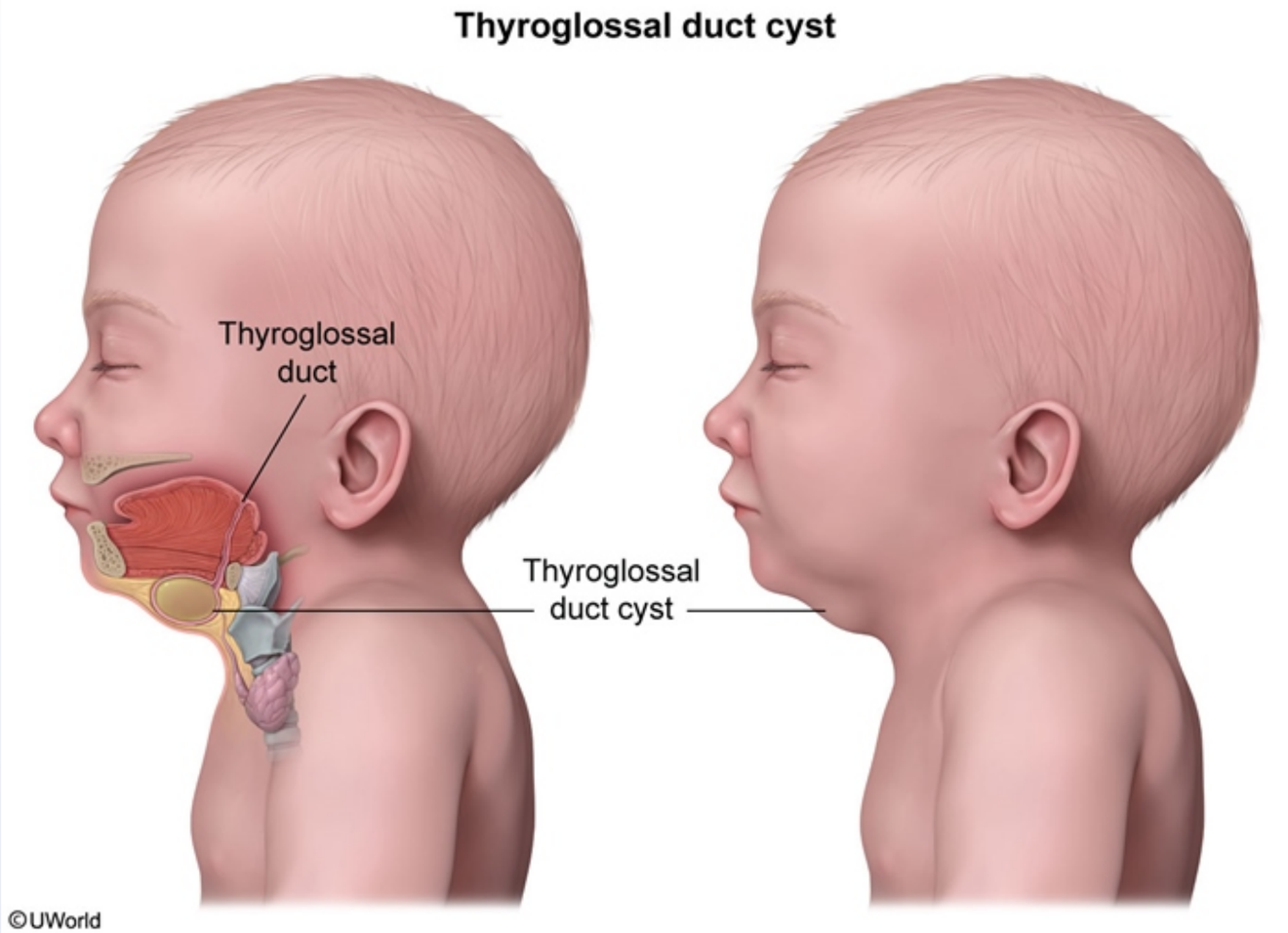

This patient has a **thyroglossal duct cyst** (TDC), which presents as a **midline mass** that characteristically **moves superiorly** with protrusion of the tongue or swallowing. A TDC is often detected when it becomes secondarily infected after an upper respiratory tract infection, leading to erythema and tenderness. It may also be noted incidentally during evaluation of throat or neck symptoms.

The **thyroid gland** is formed as an outpouching from the pharyngeal epithelium at the base of the tongue. It then descends to the base of the anterior neck via the thyroglossal duct, which extends from the foramen cecum on the dorsal surface of the tongue to the superior border of the

This patient has a **thyroglossal duct cyst** (TDC), which presents as a **midline mass** that characteristically **moves superiorly** with protrusion of the tongue or swallowing. A TDC is often detected when it becomes secondarily infected after an upper respiratory tract infection, leading to erythema and tenderness. It may also be noted incidentally during evaluation of throat or neck symptoms.

The **thyroid gland** is formed as an outpouching from the pharyngeal epithelium at the base of the tongue. It then descends to the base of the anterior neck via the thyroglossal duct, which extends from the foramen cecum on the dorsal surface of the tongue to the superior border of the thyroid isthmus. If the duct fails to atrophy normally, a TDC can develop from the epithelial remnants within the duct. Because the tract connects to the base of the tongue, protrusion or swallowing causes the TDC to move superiorly. Ectopic thyroid tissue may also form and can reside anywhere along the thyroglossal duct's path.

(Choice A) A paraganglioma is a neuroendocrine tumor that arises from extraadrenal, autonomic paraganglia (eg, carotid body paraganglia) due to the abnormal migration of neural crest cells. Carotid body paragangliomas typically present as lateral neck masses.

(Choice B) Cervical implantation of thymic tissue can result in ectopic thymic cysts, which are rare lesions that may develop along the descent of the thymus (angle of the jaw to the mediastinum). They are typically unilateral (left more often than right) rather than midline.

(Choice C) A cystic hygroma results from abnormal lymphatic development, leading to dilated lymphatic vessels. It presents at birth as a soft mass at the posterior base or lateral aspect of the neck. It would not typically be at the midline or rise with swallowing.

(Choice E) A branchial cleft cyst is an embryologic remnant of branchial arch structures that presents as a lateral (rather than midline) neck mass. A sinus tract or fistula may also be present.

(Choice F) Trapping of skin structures (eg, hair follicles, sebaceous glands) along embryonic fusion lines results in the formation of a dermoid cyst within the subcutaneous tissue. It presents as a midline neck mass but, in contrast to this patient's neck mass, does not move with tongue protrusion or swallowing.

Educational objective:
Thyroglossal duct cysts form from epithelial remnants of the thyroglossal duct along the path of thyroid descent. They present as midline masses that rise with swallowing or tongue protrusion.

References

- Thyroglossal duct cysts: anatomy, embryology and treatment.

anywhere along the thyroglossal duct's path.

(Choice A) A paraganglioma is a neuroendocrine tumor that arises from extraadrenal, autonomic paraganglia (eg, carotid body paraganglia) due to the abnormal migration of neural crest cells. Carotid body paragangliomas typically present as lateral neck masses.

(Choice B) Cervical implantation of thymic tissue can result in ectopic thymic cysts, which are rare lesions that may develop along the descent of the thymus (angle of the jaw to the mediastinum). They are typically unilateral (left more often than right) rather than midline.

(Choice C) A cystic hygroma results from abnormal lymphatic development, leading to dilated lymphatic vessels. It presents at birth as a soft mass at the posterior base or lateral aspect of the neck. It would not typically be at the midline or rise with swallowing.

(Choice E) A branchial cleft cyst is an embryologic remnant of branchial arch structures that presents as a lateral (rather than midline) neck mass. A sinus tract or fistula may also be present.

(Choice F) Trapping of skin structures (eg, hair follicles, sebaceous glands) along embryonic fusion lines results in the formation of a dermoid cyst within the subcutaneous tissue. It presents as a midline neck mass but, in contrast to this patient's neck mass, does not move with tongue protrusion or swallowing.

Educational objective:
Thyroglossal duct cysts form from epithelial remnants of the thyroglossal duct along the path of thyroid descent. They present as midline masses that rise with swallowing or tongue protrusion.

References

- Thyroglossal duct cysts: anatomy, embryology and treatment.
- Congenital cystic lesions of the head and neck.
- Congenital cystic neck masses: embryology and imaging appearances, with clinicopathological correlation.

Embryology	Ear, Nose & Throat (ENT)	Thyroglossal duct cyst
Subject	System	Topic

Copyright © UWorld. All rights reserved.

1
2
3
4
5
6
7
8
9
10
11
12
13
14
15
16
17
18
19
20
21
22
23
24

Exhibit Display

Thyroid migration

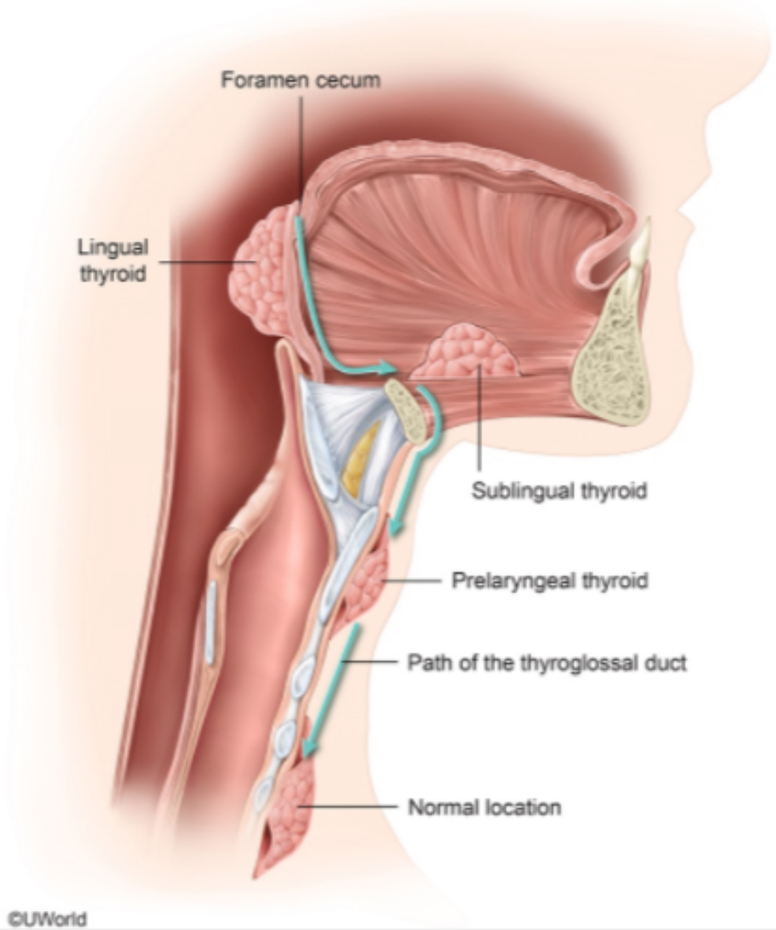

Zoom In
Zoom Out
Reset
Add To Flash Card

Thyroglossal duct cysts form from epithelial remnants of the thyroglossal duct along the path of thyroid descent. They present as midline masses

1
2
3
4
5
6
7
8
9
10
11
12
13
14
15
16
17
18
19
20
21
22
23
24

A 23-year-old man has 2 days of fever, cough, sore throat, and runny nose. His temperature is 38 C (100.4 F). Lung sounds are clear to auscultation. A nasopharyngeal swab is obtained. Naked viral particles are seen, and purified RNA molecules are extracted from these particles. Once introduced into human cells, the purified RNA molecules induce viral protein synthesis and viral genome replication. Which of the following is the most likely cause of this patient's symptoms?

A. HIV

B. Influenza virus type A

C. Respiratory syncytial virus

D. Rhinovirus

E. Rotavirus

Submit

A 23-year-old man has 2 days of fever, cough, sore throat, and runny nose. His temperature is 38 C (100.4 F). Lung sounds are clear to auscultation. A nasopharyngeal swab is obtained. Naked viral particles are seen, and purified RNA molecules are extracted from these particles. Once introduced into human cells, the purified RNA molecules induce viral protein synthesis and viral genome replication. Which of the following is the most likely cause of this patient's symptoms?

A. HIV (5%)
B. Influenza virus type A (16%)
C. Respiratory syncytial virus (6%)
✓ D. Rhinovirus (68%)
E. Rotavirus (3%)

Omitted
Correct answer
D

68%
Answered correctly

02 secs
Time Spent

04/18/2020
Last Updated

Explanation

For an RNA molecule **purified** from a virus (ie, without viral capsid or envelope) to be infectious (ie, able to induce viral protein synthesis and genome replication in the host cell) on its own, it must act as mRNA capable of using the host's intracellular machinery for translation. In other words, the purified RNA molecule must be **single-stranded** (SS) and **positive (+) sense**, or SS(+). The question describes a naked (ie, nonenveloped) virus with SS(+) RNA. Of the viruses listed, only rhinovirus (a picornavirus) has these features. Generally, only RNA molecules purified from SS(+) viruses are infectious; purified SS negative (–) sense RNA molecules and double-stranded (ds) RNA molecules are not as they require additional enzymes.

Explanation

For an RNA molecule **purified** from a virus (ie, without viral capsid or envelope) to be infectious (ie, able to induce viral protein synthesis and genome replication in the host cell) on its own, it must act as mRNA capable of using the host's intracellular machinery for translation. In other words, the purified RNA molecule must be **single-stranded** (SS) and **positive (+) sense**, or SS(+). The question describes a naked (ie, nonenveloped) virus with SS(+) RNA. Of the viruses listed, only rhinovirus (a picornavirus) has these features. Generally, only RNA molecules purified from SS(+) viruses are infectious; purified SS negative (–) sense RNA molecules and double-stranded (ds) RNA molecules are not as they require additional enzymes.

(Choice A) HIV is a retrovirus that contains SS(+) RNA. However, viral infectivity requires the action of reverse transcriptase for integration into the host genome; purified RNA by itself cannot cause infection. In addition, HIV is enveloped, unlike the particles isolated from this patient.

(Choices B and C) Influenza A is an orthomyxovirus that contains SS(–) RNA; similarly, respiratory syncytial virus is a paramyxovirus that contains SS(–) RNA. For these viruses to replicate in a host cell, an RNA-dependent RNA polymerase must also gain entry into the host cell.

(Choice E) Rotavirus is a reovirus containing dsRNA. Its purified RNA is therefore incapable of inducing viral protein synthesis in a host cell on its own (ie, it is non-infectious). For this virus to replicate in a host cell, a specific viral RNA polymerase present in the intact virion must also gain entry into the host cell.

Educational objective:
For a purified RNA molecule to induce viral protein synthesis in a host cell, it must be able to act directly as mRNA using the host's intracellular machinery for translation. Therefore, in general, purified single-stranded positive-sense RNA can be infectious; single-stranded negative sense or double-stranded RNA is not.

Microbiology	Ear, Nose & Throat (ENT)	Upper respiratory tract infections
Subject	System	Topic

Copyright © UWorld. All rights reserved.

A 30-year-old woman comes to the emergency department after a seizure. The patient reports pain on the left side of her face and is unable to fully open or close her mouth. She is drooling. On examination, the jaw deviates to the right and the left mandibular condyle is very prominent with a palpable depression posterior to it. The patient is diagnosed with an anterior dislocation of the left temporomandibular joint. The jaw is most likely maintained in a dislocated position due to continued spasm of which of the following muscles?

A. Buccinator
B. Genioglossus
C. Lateral pterygoid
D. Sternocleidomastoid
E. Superior pharyngeal constrictor
F. Zygomaticus major

Submit

A 30-year-old woman comes to the emergency department after a seizure. The patient reports pain on the left side of her face and is unable to fully open or close her mouth. She is drooling. On examination, the jaw deviates to the right and the left mandibular condyle is very prominent with a palpable depression posterior to it. The patient is diagnosed with an anterior dislocation of the left temporomandibular joint. The jaw is most likely maintained in a dislocated position due to continued spasm of which of the following muscles?

- A. Buccinator (6%)
- B. Genioglossus (0%)
- ✓ C. Lateral pterygoid (85%)
- D. Sternocleidomastoid (1%)
- E. Superior pharyngeal constrictor (0%)
- F. Zygomaticus major (4%)

Omitted
Correct answer
C

85%
Answered correctly

02 secs
Time Spent

05/15/2020
Last Updated

Explanation

Lateral pterygoid function

Lateral pterygoid

1
2
3
4
5
6
7
8
9
10
11
12
13
14
15
16
17
18
19
20
21
22
23
24

Lateral pterygoid function

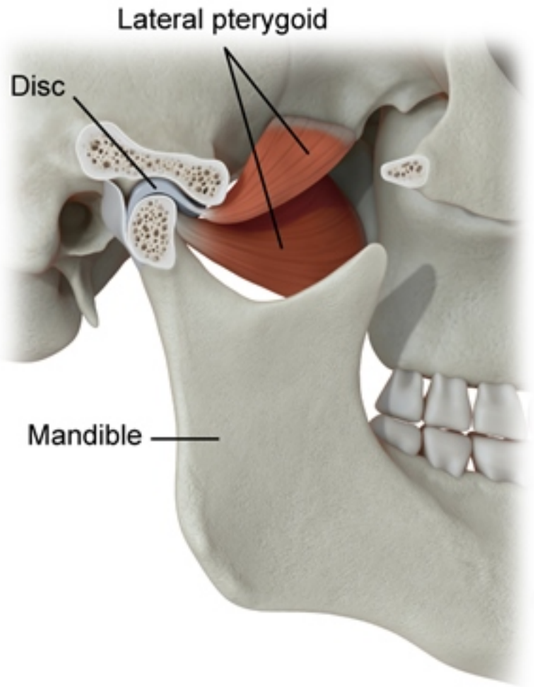

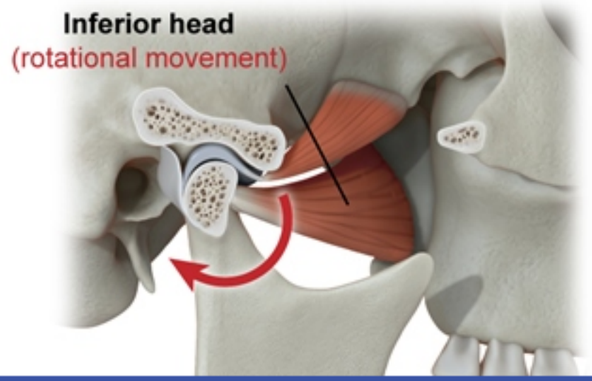

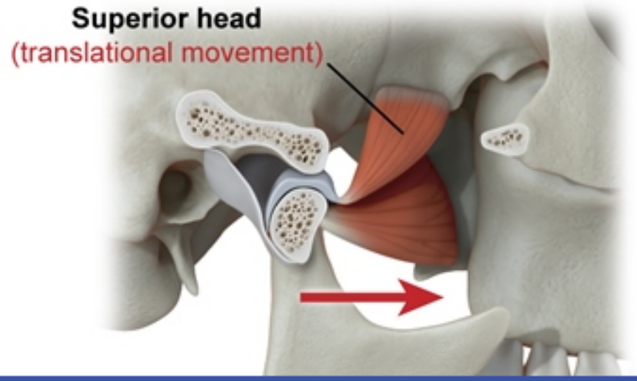

1
2
3
4
5
6
7
8
9
10
11
12
13
14
15
16
17
18
19
20
21
22
23
24

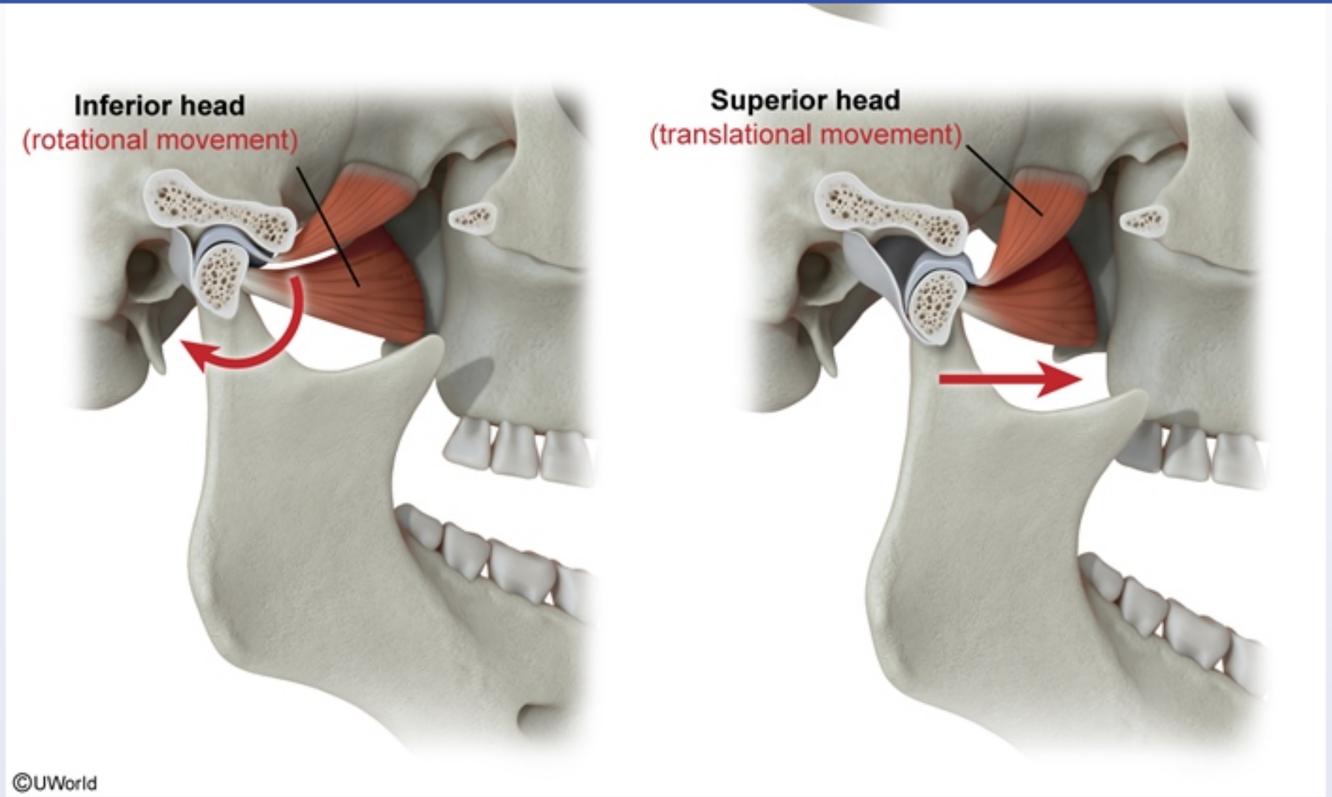

This patient has an anterior dislocation of the **temporomandibular joint** (TMJ), the synovial joint that opens and closes the jaw. The joint is formed by the mandibular condyle that sits in the glenoid fossa of the squamous portion of the temporal bone.

TMJ opening involves a complex movement that has both hinge and sliding components:

- The initial movement is rotational (ie, hinge) and driven by the **lateral pterygoid muscles**, which are the only muscles of mastication that aid in **depressing the mandible** (ie, opening the jaw).
- As the jaw opens, the ligaments become taut, stopping further rotation.
- Further action by the lateral pterygoids results in translational movement (ie, condyle slides anteriorly) that opens the jaw fully.

This patient has an anterior dislocation of the **temporomandibular joint** (TMJ), the synovial joint that opens and closes the jaw. The joint is formed by the mandibular condyle that sits in the glenoid fossa of the squamous portion of the temporal bone.

TMJ opening involves a complex movement that has both hinge and sliding components:

- The initial movement is rotational (ie, hinge) and driven by the **lateral pterygoid muscles**, which are the only muscles of mastication that aid in **depressing the mandible** (ie, opening the jaw).
- As the jaw opens, the ligaments become taut, stopping further rotation.
- Further action by the lateral pterygoids results in translational movement (ie, condyle slides anteriorly) that opens the jaw fully.

TMJ dislocation occurs when translational movement is exaggerated due to **extreme jaw opening** (eg, yawning, orotracheal intubation, **seizure**) that causes displacement of the condyle anteriorly out of the glenoid fossa. Stretching of the ligaments causes significant pain and spasm of the muscles of mastication. This **muscle spasm** (specifically of the lateral pterygoids that aid jaw opening) **prevents spontaneous resolution** of the dislocation; manual reduction is usually necessary.

(Choice A) The buccinator muscle underlies the cheek. It holds the cheek close to the teeth to control food boluses during chewing but is not involved in movement of the jaw.

(Choice B) The genioglossus muscles form the body of the tongue. Although they originate on the tubercle of the mandible (and insert into the hyoid bone and the bottom of the tongue), they are responsible for tongue protrusion rather than mandibular movement.

(Choice D) The sternocleidomastoid muscles originate at the sternum and the clavicle and insert on the mastoid tip. They rotate the head (when acting independently) or flex the neck (when acting in concert).

(Choice E) The superior pharyngeal constrictor forms portions of the posterior and lateral oropharyngeal walls. Muscle contraction propels food and liquid inferiorly into the esophagus during swallowing.

(Choice F) The zygomaticus major originates from the zygomatic bone and inserts onto the angle of the mouth. Contraction pulls the angle of the mouth laterally and superiorly during a smile.

Educational objective:
The lateral pterygoid muscles are the only muscles of mastication that aid in depressing the mandible (ie, opening the jaw). Spasm of the lateral pterygoids prevents spontaneous reduction of an anterior dislocation of the temporomandibular joint.

that causes displacement of the condyle anteriorly out of the glenoid fossa. Stretching of the ligaments causes significant pain and spasm of the muscles of mastication. This **muscle spasm** (specifically of the lateral pterygoids that aid jaw opening) **prevents spontaneous resolution** of the dislocation; manual reduction is usually necessary.

(Choice A) The buccinator muscle underlies the cheek. It holds the cheek close to the teeth to control food boluses during chewing but is not involved in movement of the jaw.

(Choice B) The genioglossus muscles form the body of the tongue. Although they originate on the tubercle of the mandible (and insert into the hyoid bone and the bottom of the tongue), they are responsible for tongue protrusion rather than mandibular movement.

(Choice D) The sternocleidomastoid muscles originate at the sternum and the clavicle and insert on the mastoid tip. They rotate the head (when acting independently) or flex the neck (when acting in concert).

(Choice E) The superior pharyngeal constrictor forms portions of the posterior and lateral oropharyngeal walls. Muscle contraction propels food and liquid inferiorly into the esophagus during swallowing.

(Choice F) The zygomaticus major originates from the zygomatic bone and inserts onto the angle of the mouth. Contraction pulls the angle of the mouth laterally and superiorly during a smile.

Educational objective:
The lateral pterygoid muscles are the only muscles of mastication that aid in depressing the mandible (ie, opening the jaw). Spasm of the lateral pterygoids prevents spontaneous reduction of an anterior dislocation of the temporomandibular joint.

References

- Temporomandibular joint dislocation.
- The emerging role of botulinum toxin in the treatment of temporomandibular disorders

Anatomy	Ear, Nose & Throat (ENT)	Temporomandibular disorders
Subject	System	Topic

Copyright © UWorld. All rights reserved.

1
2
3
4
5
6
7
8
9
10
11
12
13
14
15
16
17
18
19
20
21
22
23
24

that causes displacement of the condyle anteriorly out of the glenoid fossa. Stretching of the ligaments causes significant pain and spasm of the

Exhibit Display

Muscles of facial expression

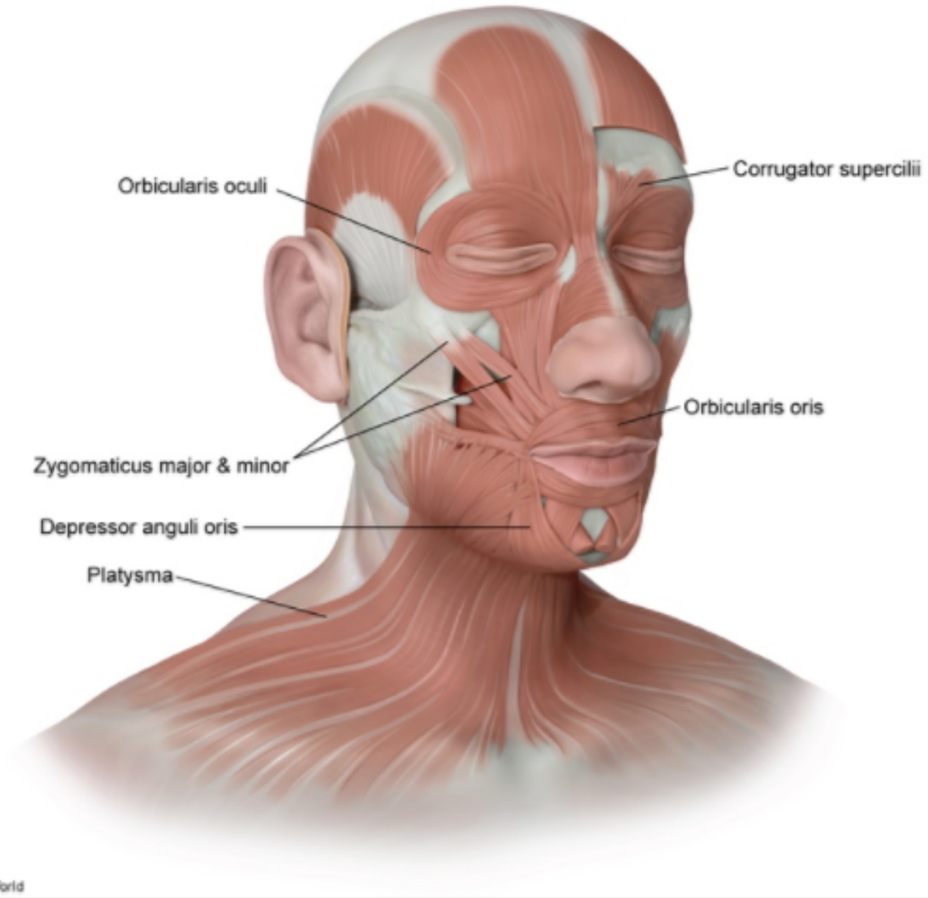

Zoom In Zoom Out Reset Add To Flash Card

A 65-year-old man comes to the office with a 4-month history of persistent left ear pain that is slowly worsening. He is also having some difficulty swallowing. The patient has no chronic medical conditions but has smoked 1 pack of cigarettes per day for the last 46 years. On examination, the external auditory canal is patent and the tympanic membrane is clear with no middle ear effusion. There is an enlarged lymph node in the left anterior neck. Flexible fiberoptic laryngoscopy reveals an ulcerative mass on the posterior pharyngeal wall of the hypopharynx. Involvement of which of the following nerves is most likely responsible for this patient's ear pain?

- A. Trigeminal nerve
- B. Facial nerve
- C. Vestibulocochlear nerve
- D. Vagus nerve
- E. Hypoglossal nerve
- F. Great auricular nerve

Submit

A 65-year-old man comes to the office with a 4-month history of persistent left ear pain that is slowly worsening. He is also having some difficulty swallowing. The patient has no chronic medical conditions but has smoked 1 pack of cigarettes per day for the last 46 years. On examination, the external auditory canal is patent and the tympanic membrane is clear with no middle ear effusion. There is an enlarged lymph node in the left anterior neck. Flexible fiberoptic laryngoscopy reveals an ulcerative mass on the posterior pharyngeal wall of the hypopharynx. Involvement of which of the following nerves is most likely responsible for this patient's ear pain?

- A. Trigeminal nerve (11%)
- B. Facial nerve (13%)
- C. Vestibulocochlear nerve (2%)
- ✓ D. Vagus nerve (57%)
- E. Hypoglossal nerve (5%)
- F. Great auricular nerve (9%)

Omitted
Correct answer
D

57%
Answered correctly

03 secs
Time Spent

04/30/2020
Last Updated

Explanation

Referred otalgia

Referred otalgia

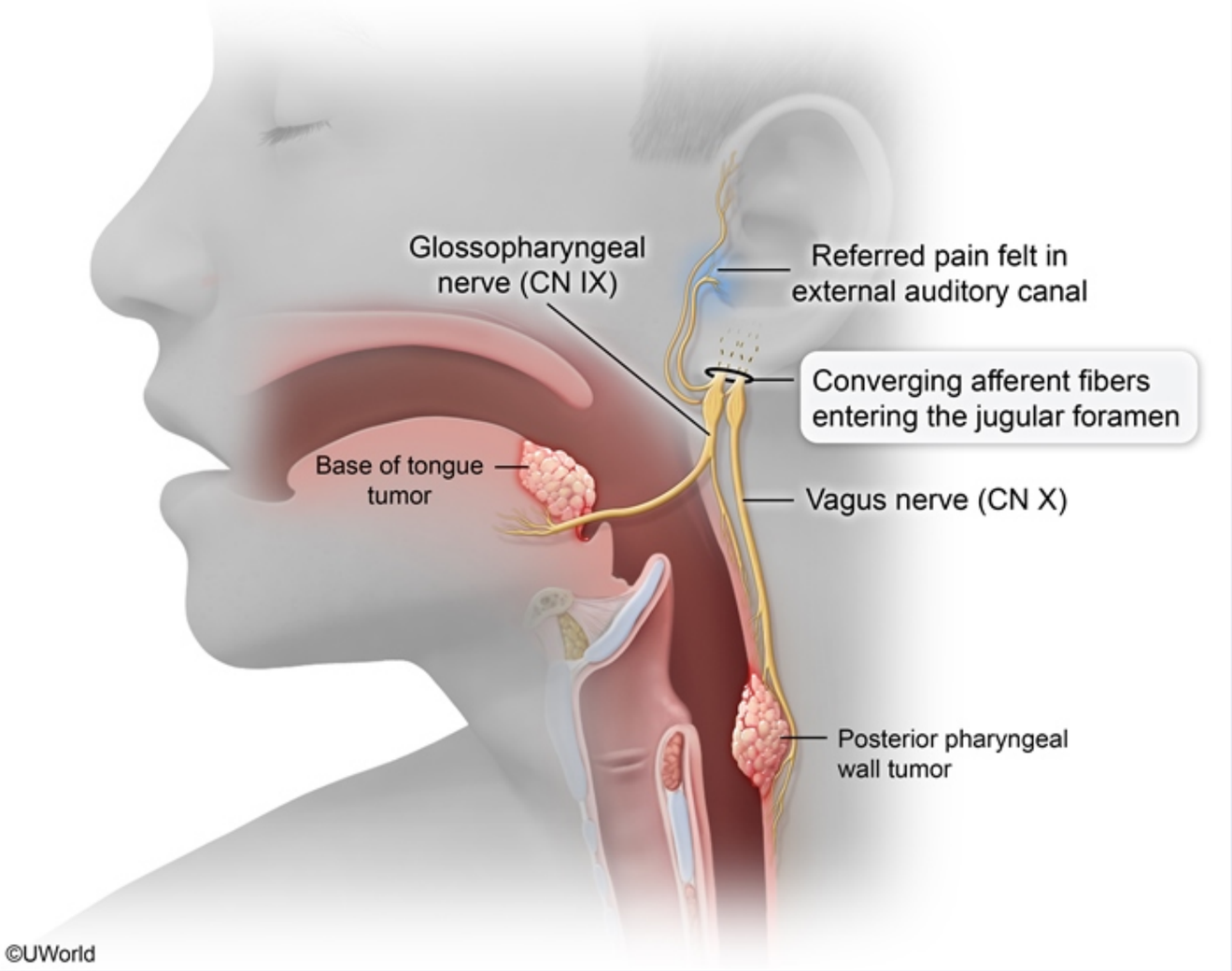

This patient has **otalgia** in the setting of a normal ear examination, which is likely **referred pain** (pain perceived at a different site than its true origin). Further evaluation shows an ulcerative mass in the hypopharynx with an enlarged lymph node, which is consistent with **mucosal head**

©UWorld

This patient has **otalgia** in the setting of a normal ear examination, which is likely **referred pain** (pain perceived at a different site than its true origin). Further evaluation shows an ulcerative mass in the hypopharynx with an enlarged lymph node, which is consistent with **mucosal head and neck squamous cell carcinoma** (HNSCC).

Many sources of pain in the head and neck can be referred to the ear because several cranial nerves also innervate parts of the ear. Common causes of referred ear pain include temporomandibular joint disease, dental disease, or cancer affecting the tongue base, hypopharynx, or larynx.

This patient's referred otalgia is most likely due to his hypopharyngeal carcinoma causing irritation of the **vagus nerve** (CN X). The vagus nerve has afferent fibers innervating the larynx and **hypopharynx** and also has a branch that provides afferent sensory input from the external auditory canal. Similarly, the **glossopharyngeal nerve** (CN IX), which innervates the upper pharynx and base of tongue, also provides sensory innervation to the external auditory canal and can contribute to referred otalgia from tumors in these areas.

(Choices A, B, and F) The trigeminal nerve (CN V) provides sensory innervation for much of the face, including parts of the ear. The facial nerve (CN VII) and great auricular nerve (originates from C2 and C3) innervate portions of the external auditory canal. Although these nerves carry sensation from the ear, they do not provide innervation to the hypopharynx.

(Choice C) The vestibulocochlear nerve (CN VIII) contributes special sensory (hearing, balance) from the ear but does not contribute to general sensation. Therefore, lesions that impact the vestibulocochlear nerve tend to cause hearing loss or imbalance (eg, vertigo) rather than pain.

(Choice E) The hypoglossal nerve (CN XII) innervates the muscles of the tongue. It has motor function only, so dysfunction tends to produce weakness (eg, deviation of the tongue) rather than pain.

Educational objective:
Referred otalgia is common in head and neck pathology because many cranial nerves innervate the ear (eg, CN V, VII, IX, X). In particular, tumors in the hypopharynx, larynx, or base of tongue cause referred otalgia due to sensory contributions from the glossopharyngeal and vagus nerves.

Anatomy	Ear, Nose & Throat (ENT)	Head and neck cancers
Subject	System	Topic

A newborn girl is evaluated in the neonatal intensive care unit for difficulty breathing. The patient was born at term via spontaneous vaginal delivery. Since birth, she has had difficulty breathing with loud snoring sounds and intermittent oxygen desaturations. She has been unable to breastfeed due to her breathing problems. Breathing improves significantly when the patient is placed in a prone position. On examination, there is a small mandible, posteriorly displaced tongue, and U-shaped cleft palate. The abnormalities described represent an example of which of the following?

A. Association
B. Disruption
C. Imprinting
D. Sequence
E. Syndrome

Submit

A newborn girl is evaluated in the neonatal intensive care unit for difficulty breathing. The patient was born at term via spontaneous vaginal delivery. Since birth, she has had difficulty breathing with loud snoring sounds and intermittent oxygen desaturations. She has been unable to breastfeed due to her breathing problems. Breathing improves significantly when the patient is placed in a prone position. On examination, there is a small mandible, posteriorly displaced tongue, and U-shaped cleft palate. The abnormalities described represent an example of which of the following?

- A. Association (6%)
- B. Disruption (15%)
- C. Imprinting (1%)
- ✓ D. Sequence (35%)
- E. Syndrome (41%)

Omitted
Correct answer
D

35%
Answered correctly

02 secs
Time Spent

05/07/2020
Last Updated

Explanation

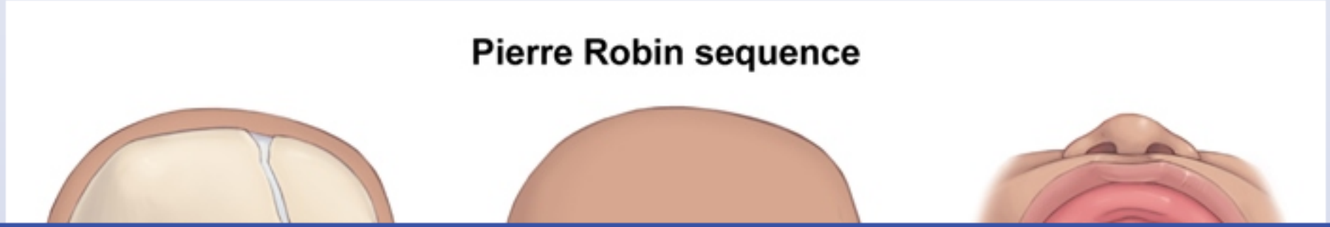

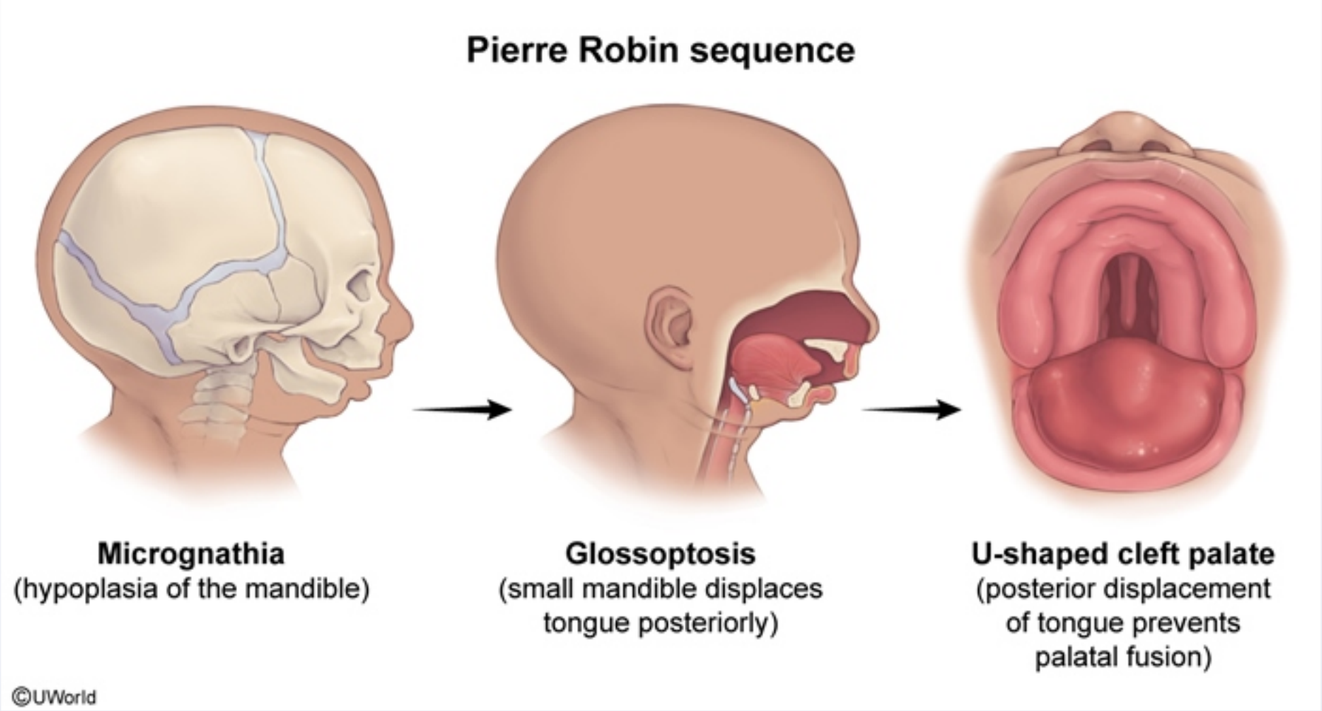

This patient has a small mandible, posteriorly displaced tongue, and U-shaped cleft palate, which is consistent with **Pierre Robin sequence**. A sequence occurs when a **single developmental defect** causes a **cascade of additional malformations**.

In Pierre Robin sequence, hypoplasia of the mandibular prominence leads to **micrognathia**. Severe micrognathia causes posterior displacement of the tongue **(glossoptosis)**, which blocks fusion of the palatine shelves, resulting in a **cleft palate** that is characteristically U-shaped. Difficulty breathing occurs because the tongue prolapses into the posterior oropharynx, blocking airflow. Breathing improves when the patient is in a prone position because gravity pulls the tongue anteriorly, opening the airway.

(Choice A) An association is a collection of malformations that are often seen together and do not have a known, common cause (eg, VACTERL association).

(Choice B) A disruption occurs when an external insult (rather than a genetic defect) interrupts and arrests normal fetal development (eg, when an amniotic band disrupts limb development). No specific external insult has been linked to Pierre Robin sequence, and most cases result from

©UWorld

This patient has a small mandible, posteriorly displaced tongue, and U-shaped cleft palate, which is consistent with **Pierre Robin sequence**. A sequence occurs when a **single developmental defect** causes a **cascade of additional malformations**.

In Pierre Robin sequence, hypoplasia of the mandibular prominence leads to **micrognathia**. Severe micrognathia causes posterior displacement of the tongue **(glossoptosis)**, which blocks fusion of the palatine shelves, resulting in a **cleft palate** that is characteristically U-shaped. Difficulty breathing occurs because the tongue prolapses into the posterior oropharynx, blocking airflow. Breathing improves when the patient is in a prone position because gravity pulls the tongue anteriorly, opening the airway.

(Choice A) An association is a collection of malformations that are often seen together and do not have a known, common cause (eg, VACTERL association).

(Choice B) A disruption occurs when an external insult (rather than a genetic defect) interrupts and arrests normal fetal development (eg, when an amniotic band disrupts limb development). No specific external insult has been linked to Pierre Robin sequence, and most cases result from genetic abnormalities.

(Choice C) Genomic imprinting is a normal process that refers to selective activation of gene expression depending on the parent of origin. Aberrant imprinting occurs with uniparental disomy (ie, when a person receives 2 copies of a chromosome from the same parent and no copy from the other parent). Prader-Willi syndrome and Angelman syndrome (15q) are examples of conditions caused by dysfunctional imprinting.

(Choice E) A syndrome is a collection of malformations that have a common cause but are not related anatomically. For example, upslanting palpebral fissures, atrioventricular canal defect, and single palmar crease are all due to trisomy 21.

Educational objective:
Pierre Robin is characterized as a sequence because the primary defect (hypoplasia of the mandibular prominence) leads to a cascade of further malformations (ie, micrognathia, posteriorly displaced tongue, U-shaped cleft palate).

Embryology	Ear, Nose & Throat (ENT)	Craniofacial anomalies
Subject	System	Topic

Copyright © UWorld. All rights reserved.

This patient has a small mandible, posteriorly displaced tongue, and U-shaped cleft palate, which is consistent with **Pierre Robin sequence**. A sequence occurs when a

In Pierre Robin sequence, ent
of the tongue **(glossoptos** lty
breathing occurs because one
position because gravity p

(Choice A) An associatio RL
association).

(Choice B) A disruption c en
an amniotic band disrupts m
genetic abnormalities.

(Choice C) Genomic imp
Aberrant imprinting occurs from
the other parent). Prader-

(Choice E) A syndrome i
palpebral fissures, atriove

Educational objective:
Pierre Robin is characteriz her
malformations (ie, microgr

Embryology — Subject
Ear, N — System

Exhibit Display

VACTERL association
V: vertebral anomalies **A**: anal atresia **C**: cardiac defects **TE**: tracheoesophageal fistula **R**: renal anomalies **L**: limb anomalies

Add To Flash Card

Copyright © UWorld. All rights reserved.

1
2
3
4
5
6
7
8
9
10
11
12
13
14
15
16
17
18
19
20
21
22
23
24

Exhibit Display

Features of Down syndrome

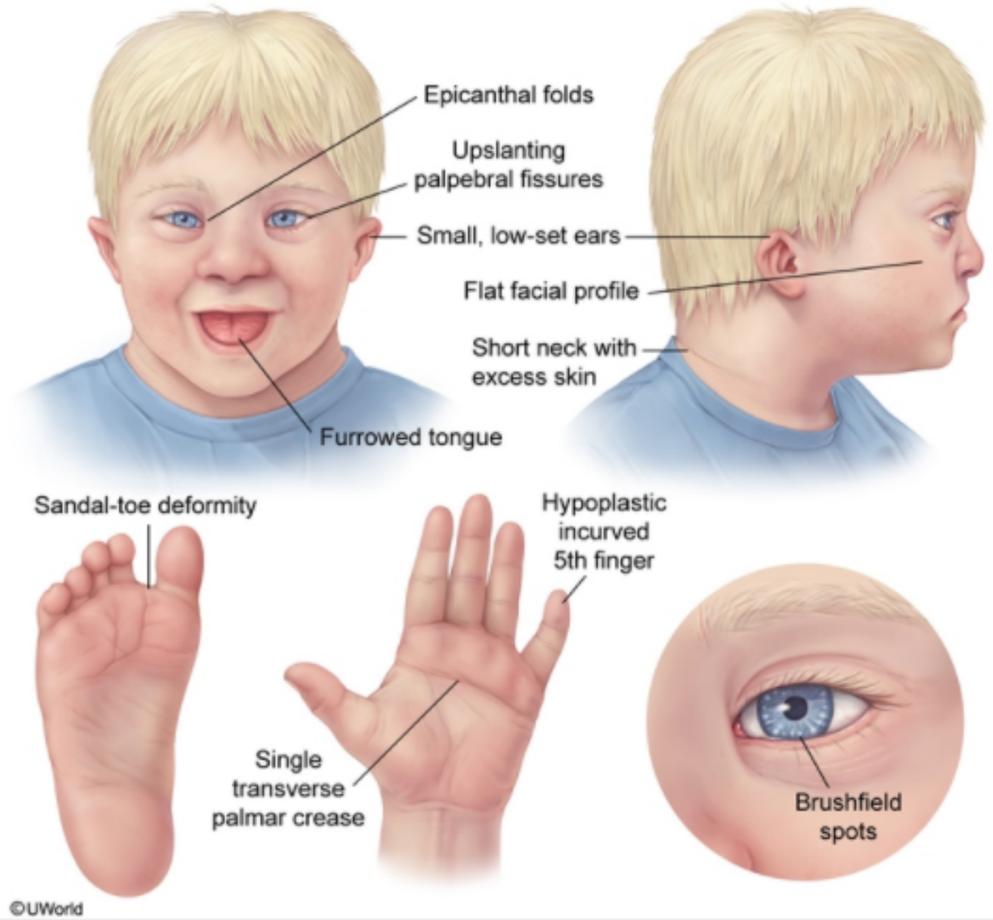

Zoom In Zoom Out Reset Add To Flash Card

A 54-year-old woman comes to the clinic due to difficulty hearing for the past few weeks. During the neurologic examination, the physician assesses her hearing using a vibrating tuning fork. The handle of the tuning fork is placed on her left mastoid process until the sound is no longer audible. The tines are then quickly placed near the patient's left auditory meatus, and she reports hearing no sound. When the handle of the vibrating fork is placed on the middle of her forehead, she hears the vibration more strongly in her left ear than her right. This patient is most likely experiencing which of the following types of hearing loss?

A. Conductive loss in both ears
B. Conductive loss in left ear
C. Conductive loss in right ear
D. Sensorineural loss in both ears
E. Sensorineural loss in left ear
F. Sensorineural loss in right ear

Submit

A 54-year-old woman comes to the clinic due to difficulty hearing for the past few weeks. During the neurologic examination, the physician assesses her hearing using a vibrating tuning fork. The handle of the tuning fork is placed on her left mastoid process until the sound is no longer audible. The tines are then quickly placed near the patient's left auditory meatus, and she reports hearing no sound. When the handle of the vibrating fork is placed on the middle of her forehead, she hears the vibration more strongly in her left ear than her right. This patient is most likely experiencing which of the following types of hearing loss?

- A. Conductive loss in both ears (0%)
- ✓ B. Conductive loss in left ear (68%)
- C. Conductive loss in right ear (5%)
- D. Sensorineural loss in both ears (1%)
- E. Sensorineural loss in left ear (20%)
- F. Sensorineural loss in right ear (3%)

Omitted
Correct answer
B

68%
Answered correctly

02 secs
Time Spent

05/03/2020
Last Updated

Explanation

Interpretation of Weber & Rinne tests		
	Rinne result	Weber result

Interpretation of Weber & Rinne tests		
	Rinne result	**Weber result**
Normal	AC >BC bilaterally	Midline
Sensorineural hearing loss		Lateralizes to **unaffected** ear
Conductive hearing loss	BC >AC in **affected** ear, AC >BC in unaffected ear	Lateralizes to **affected** ear

AC = air conduction; BC = bone conduction.

©UWorld

Hearing loss is classified as either conductive (impaired transmission of air vibrations to inner ear) or sensorineural (involving the cochlea or auditory nerve). The Rinne and Weber tests can be used to help determine the type of hearing loss.

The **Rinne test** compares air versus bone conduction (via the mastoid bone). As the vibration of the tuning fork fades, air-conducted sound is normally louder and heard longer than bone-conducted sound. The Rinne test is considered positive (normal) if the sound is heard best at the external auditory meatus (air conduction) and negative (abnormal) if the patient hears the vibration better at the mastoid (bone conduction).

- Bone conduction greater than air conduction suggests conductive hearing loss.

The **Weber test** is performed by placing a vibrating tuning fork on the middle of forehead equidistant from both ears. The vibration carried by bone conduction is normally heard equally in both ears; vibration heard louder in one ear is abnormal.

- Conductive hearing loss causes lateralization to the affected ear as the conduction deficit masks the ambient noise in the room, allowing the vibration to be better heard.

AC = air conduction; BC = bone conduction.

©UWorld

Hearing loss is classified as either conductive (impaired transmission of air vibrations to inner ear) or sensorineural (involving the cochlea or auditory nerve). The Rinne and Weber tests can be used to help determine the type of hearing loss.

The **Rinne test** compares air versus bone conduction (via the mastoid bone). As the vibration of the tuning fork fades, air-conducted sound is normally louder and heard longer than bone-conducted sound. The Rinne test is considered positive (normal) if the sound is heard best at the external auditory meatus (air conduction) and negative (abnormal) if the patient hears the vibration better at the mastoid (bone conduction).

- Bone conduction greater than air conduction suggests conductive hearing loss.

The **Weber test** is performed by placing a vibrating tuning fork on the middle of forehead equidistant from both ears. The vibration carried by bone conduction is normally heard equally in both ears; vibration heard louder in one ear is abnormal.

- Conductive hearing loss causes lateralization to the affected ear as the conduction deficit masks the ambient noise in the room, allowing the vibration to be better heard.
- Sensorineural hearing loss causes lateralization to the unaffected ear as the unimpaired inner ear can better sense the vibration.

The Rinne test is abnormal in this patient's left ear, and the Weber test lateralizes to her left ear. These findings suggest **conductive hearing loss** in the left ear.

Educational objective:
In conductive hearing loss, bone conduction will be greater than air conduction (abnormal Rinne test), and the Weber test will lateralize to the affected ear. In sensorineural hearing loss, air conduction will be greater than bone conduction (normal Rinne test), and the Weber test will lateralize to the unaffected ear.

Physiology	Ear, Nose & Throat (ENT)	Hearing loss
Subject	System	Topic

Copyright © UWorld. All rights reserved.

A 36-year-old man is rushed to the emergency department after sudden onset of shortness of breath and difficulty swallowing. He has visited the emergency department several times before due to food and skin allergies. The patient is unconscious on arrival. Examination shows excessive accessory respiratory muscle use and edematous swelling of the face, lips, and tongue. There is also scattered urticaria over the upper body. Attempts at intubation are unsuccessful due to massive soft tissue edema involving the pharynx. A decision is made to perform an emergency cricothyrotomy. The incisions made during this procedure will most likely pass through which of the following structures?

A. Buccopharyngeal fascia and platysma

B. Platysma and thyroid isthmus

C. Pretracheal fascia and cricoid cartilage

D. Pretracheal fascia and prevertebral fascia

E. Superficial cervical fascia and cricothyroid membrane

Submit

A 36-year-old man is rushed to the emergency department after sudden onset of shortness of breath and difficulty swallowing. He has visited the emergency department several times before due to food and skin allergies. The patient is unconscious on arrival. Examination shows excessive accessory respiratory muscle use and edematous swelling of the face, lips, and tongue. There is also scattered urticaria over the upper body. Attempts at intubation are unsuccessful due to massive soft tissue edema involving the pharynx. A decision is made to perform an emergency cricothyrotomy. The incisions made during this procedure will most likely pass through which of the following structures?

A. Buccopharyngeal fascia and platysma (1%)

B. Platysma and thyroid isthmus (3%)

C. Pretracheal fascia and cricoid cartilage (29%)

D. Pretracheal fascia and prevertebral fascia (1%)

✓ E. Superficial cervical fascia and cricothyroid membrane (63%)

Omitted
Correct answer
E

63%
Answered correctly

02 secs
Time Spent

03/23/2020
Last Updated

Explanation

Cricothyrotomy

1
2
3
4
5
6
7
8
9
10
11
12
13
14
15
16
17
18
19
20
21
22
23
24

Cricothyrotomy

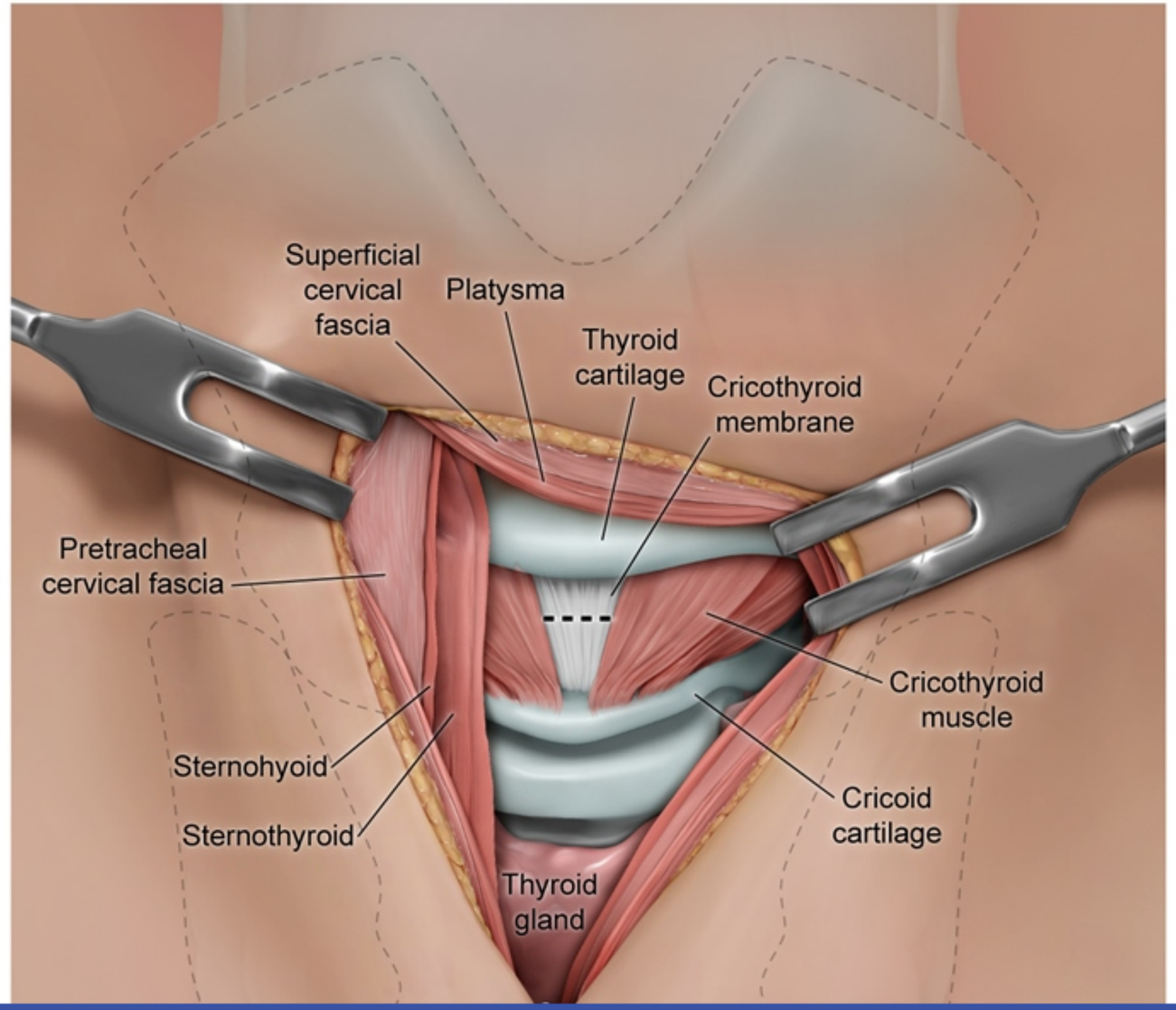

©UWorld

This patient is experiencing acute, life-threatening laryngeal edema as part of an **anaphylactic reaction** precipitated by exposure to an allergen. **Laryngeal edema** can initially present with throat tightness, difficulty swallowing, dyspnea, and hoarseness. However, the condition can **quickly progress** to compromise the airway and cause **asphyxiation**.

Cricothyrotomy is indicated when an emergency airway is required and orotracheal or nasotracheal intubation is either unsuccessful or contraindicated (eg, massive hemorrhage, vomiting, facial trauma, airway obstruction). The procedure establishes an airway through the placement of a tube between the cricoid and thyroid cartilages and requires incision through the following structures:

1. Skin
2. **Superficial cervical fascia** (including subcutaneous fat and **platysma** muscle)
3. Investing and pretracheal layers of the deep cervical fascia
4. **Cricothyroid membrane**

(Choice A) The buccopharyngeal fascia invests the pharyngeal constrictor muscles and lies anterior to the alar fascia, forming the retropharyngeal space between them. The danger space lies posterior to the retropharyngeal space (between the alar and prevertebral fascia). Retropharyngeal abscesses can drain directly into the superior mediastinum or penetrate into the danger space to extend along the entire length of the mediastinum, causing acute necrotizing mediastinitis.

(Choices B and C) The cricoid cartilage lies inferior to the thyroid cartilage at the level of the C6 vertebra, and the thyroid isthmus lies inferior to the cricoid cartilage. Incisions made during cricothyrotomy should be performed with care to prevent damage to these structures.

(Choice D) The deep cervical fascia is composed of three layers: investing, pretracheal, and prevertebral. The prevertebral layer of the deep fascia surrounds the vertebral column and spinal muscles; it is not penetrated during cricothyrotomy.

Educational objective:
Cricothyrotomy is indicated when an emergency airway is required and orotracheal or nasotracheal intubation is either unsuccessful or contraindicated. The cricothyrotomy incision passes through the superficial cervical fascia, pretracheal fascia, and the cricothyroid membrane.

Anatomy	Ear, Nose & Throat (ENT)	Airway emergency
Subject	System	Topic

1
2
3
4
5
6
7
8
9
10
11
12
13
14
15
16
17
18
19
20
21
22
23
24

Laryngeal edema can initially present with throat tightness, difficulty swallowing, dyspnea, and hoarseness. However, the condition can **quickly**

Exhibit Display

Deep neck space anatomy

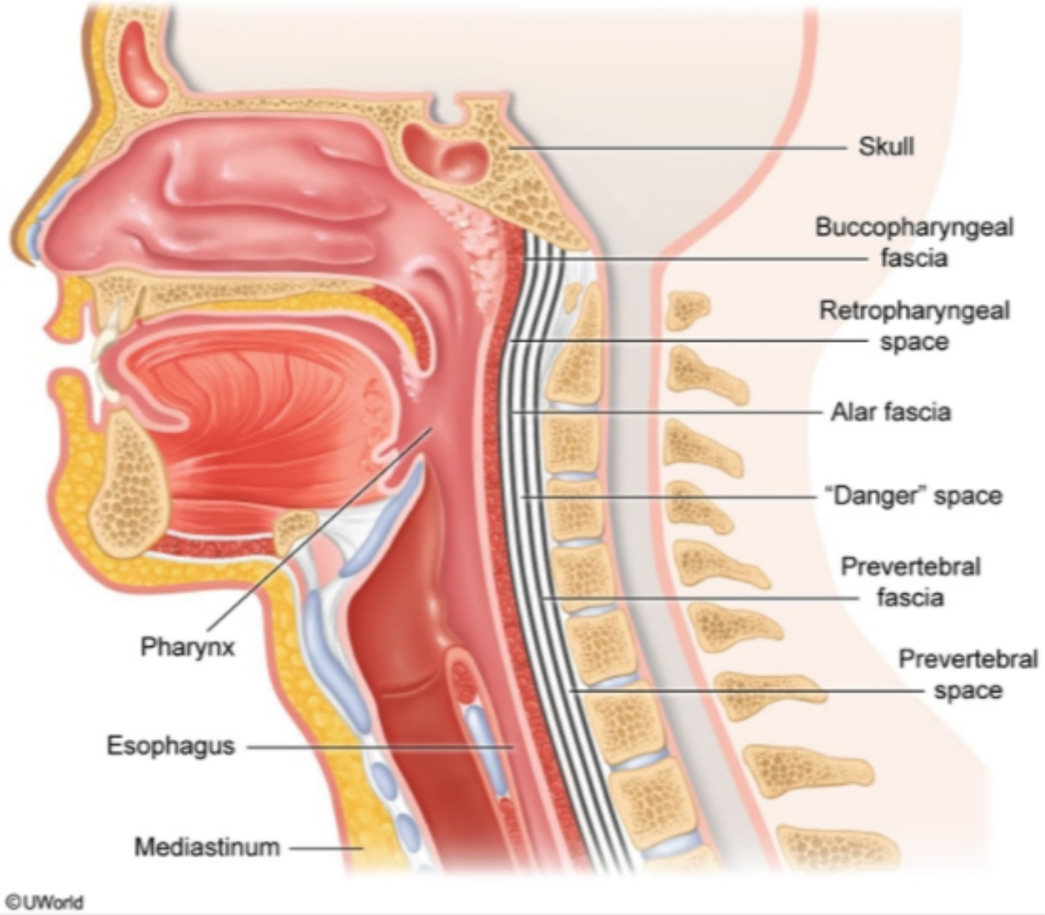

Zoom In | Zoom Out | Reset | Add To New Card | Existing Card

1
2
3
4
5
6
7
8
9
10
11
12
13
14
15
16
17
18
19
20
21
22
23
24

Laryngeal edema can initially present with throat tightness, difficulty swallowing, dyspnea, and hoarseness. However, the condition can **quickly**

Exhibit Display

Fascia of the neck

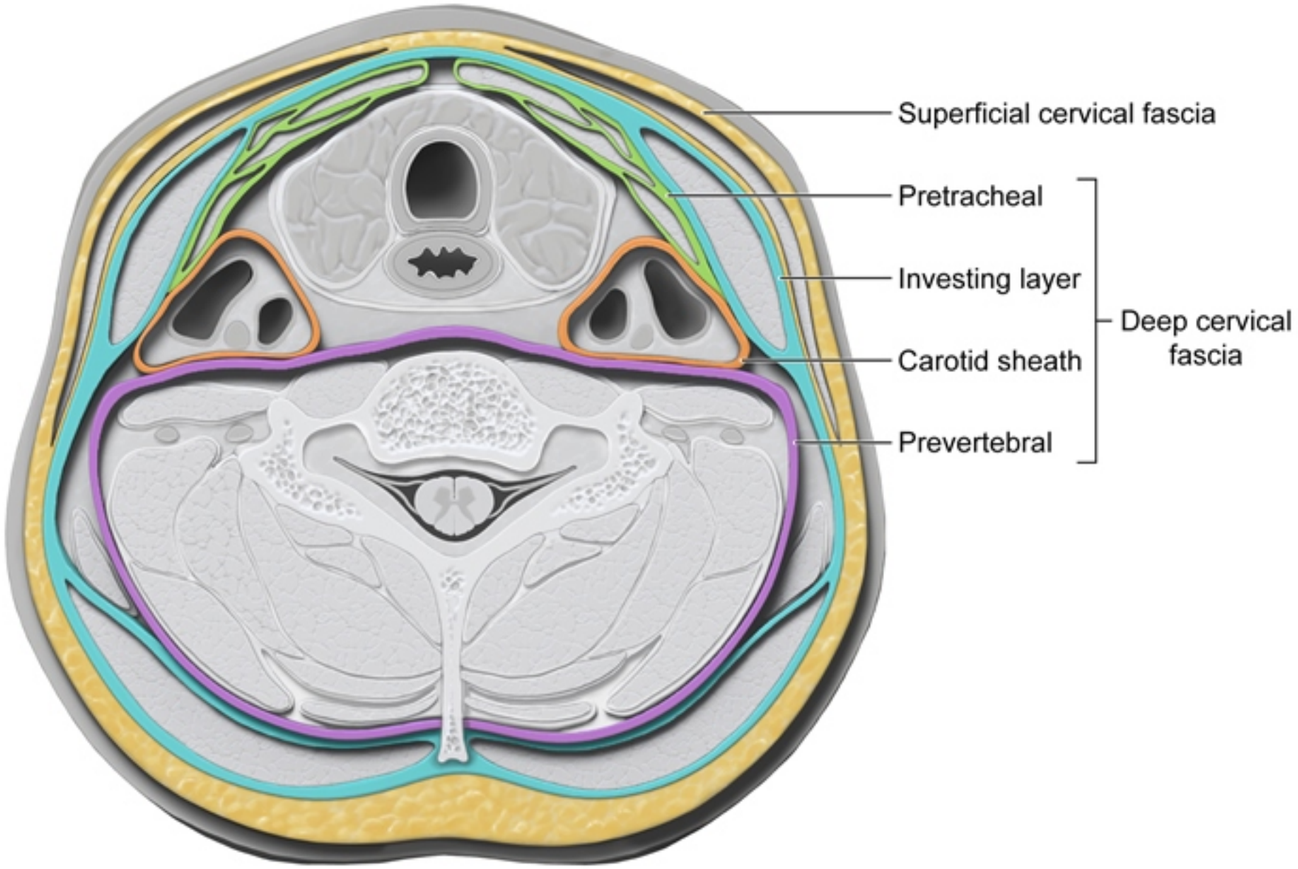

©UWorld

Zoom In | Zoom Out | Reset | Add To New Card | Existing Card

A 23-year-old man comes to the emergency department due to a sensation of food being stuck in his throat. His symptoms started 2 hours ago after eating fish at a local seafood restaurant. He has tried swallowing multiple times to clear the food with no relief. The patient has no difficulty with breathing. He does not appear to be in significant distress on physical examination. Laryngoscopy reveals a fish bone lodged in the left piriform recess. During retrieval of the fish bone, a nerve is injured deep to the mucosa overlying the recess. Which of the following is most likely to be impaired in this patient?

A. Cough reflex
B. Gag reflex
C. Mastication
D. Salivation
E. Taste sensation

Submit

A 23-year-old man comes to the emergency department due to a sensation of food being stuck in his throat. His symptoms started 2 hours ago after eating fish at a local seafood restaurant. He has tried swallowing multiple times to clear the food with no relief. The patient has no difficulty with breathing. He does not appear to be in significant distress on physical examination. Laryngoscopy reveals a fish bone lodged in the left piriform recess. During retrieval of the fish bone, a nerve is injured deep to the mucosa overlying the recess. Which of the following is most likely to be impaired in this patient?

- ✓ A. Cough reflex (39%)
- B. Gag reflex (53%)
- C. Mastication (1%)
- D. Salivation (2%)
- E. Taste sensation (4%)

Omitted
Correct answer
A

39%
Answered correctly

02 secs
Time Spent

06/01/2020
Last Updated

Explanation

Posterior view of pharynx

1
2
3
4
5
6
7
8
9
10
11
12
13
14
15
16
17
18
19
20
21
22
23
24

Posterior view of pharynx

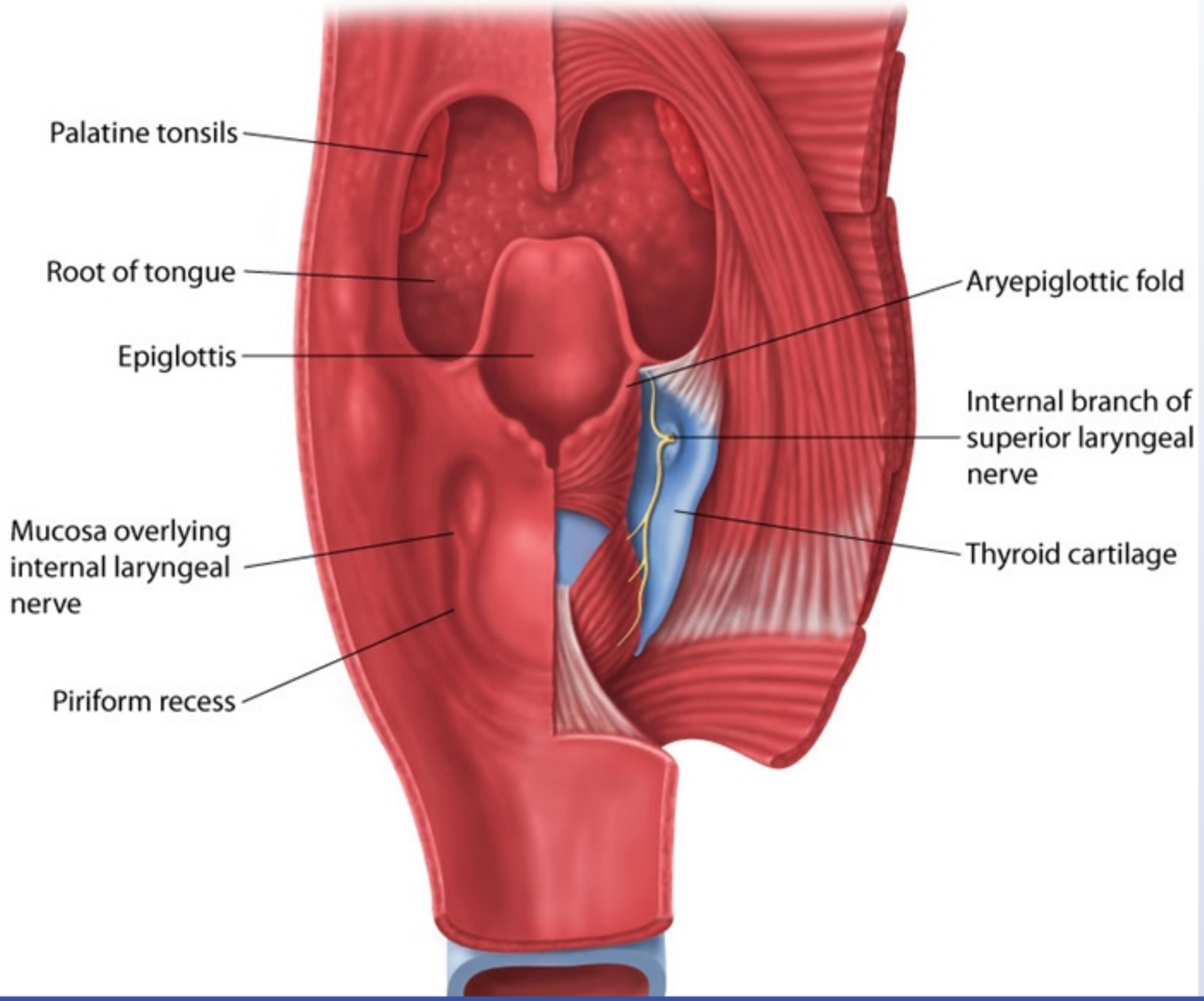

The **piriform recesses** are small cavities that lie on either side of the laryngeal orifice. They are bounded medially by the aryepiglottic folds and laterally by the thyroid cartilage and thyrohyoid membrane. During normal swallowing, food is diverted by the epiglottis laterally through the piriform recesses into the esophagus without endangering the airway.

A thin layer of mucosa overlying the piriform recess is all that protects the superficially coursing **internal laryngeal nerve**, a branch of the superior laryngeal nerve (part of the vagus nerve [CN X]). Unlike the recurrent and external laryngeal nerves that carry motor fibers to the muscles involved in vocal cord function, the internal laryngeal nerve contains only sensory and autonomic fibers. It mediates the afferent limb of the cough reflex by **carrying sensation** from the mucosa **superior to the vocal cords**.

Damage to the internal laryngeal nerve can occur when foreign bodies (eg, chicken or fish bones) become lodged in the piriform recess or during attempts to retrieve them. The resulting reduction in laryngeal sensation can **impair the cough reflex**.

(Choice B) The afferent limb of the gag reflex is mediated predominantly by the glossopharyngeal nerve (CN IX), whereas the efferent limb is carried by the vagus nerve (CN X). Although the internal laryngeal nerve is a branch of CN X, it does not carry motor fibers and is not involved in the gag reflex.

(Choice C) The muscles of mastication are innervated by the mandibular branch of the trigeminal nerve (CN V_3). This nerve is involved in the jaw jerk reflex, which is typically prominent only in patients with upper motor neuron lesions.

(Choice D) Salivation is mediated by the glossopharyngeal nerve (which innervates the parotid gland via the otic ganglion) and the facial nerve (which innervates submandibular and sublingual glands via the submandibular ganglion). These nerves do not lie in close proximity to the piriform recess.

(Choice E) Although the internal laryngeal nerve carries taste sensation from the root of the tongue and epiglottis, its role in the perception of taste is extremely minor. Taste sensation is primarily mediated by glossopharyngeal nerve (posterior one-third of the tongue and oropharynx) and facial nerve (anterior two-thirds of the tongue).

Educational objective:
The internal laryngeal nerve mediates the afferent limb of the cough reflex above the vocal cords. Foreign bodies (eg, fish bones) can become lodged in the piriform recess and may cause damage to the nerve, impairing the cough reflex.

1
2
3
4
5
6
7
8
9
10
11
12
13
14
15
16
17
18
19
20
21
22
23
24

Exhibit Display

Innervation of cricothyroid muscle

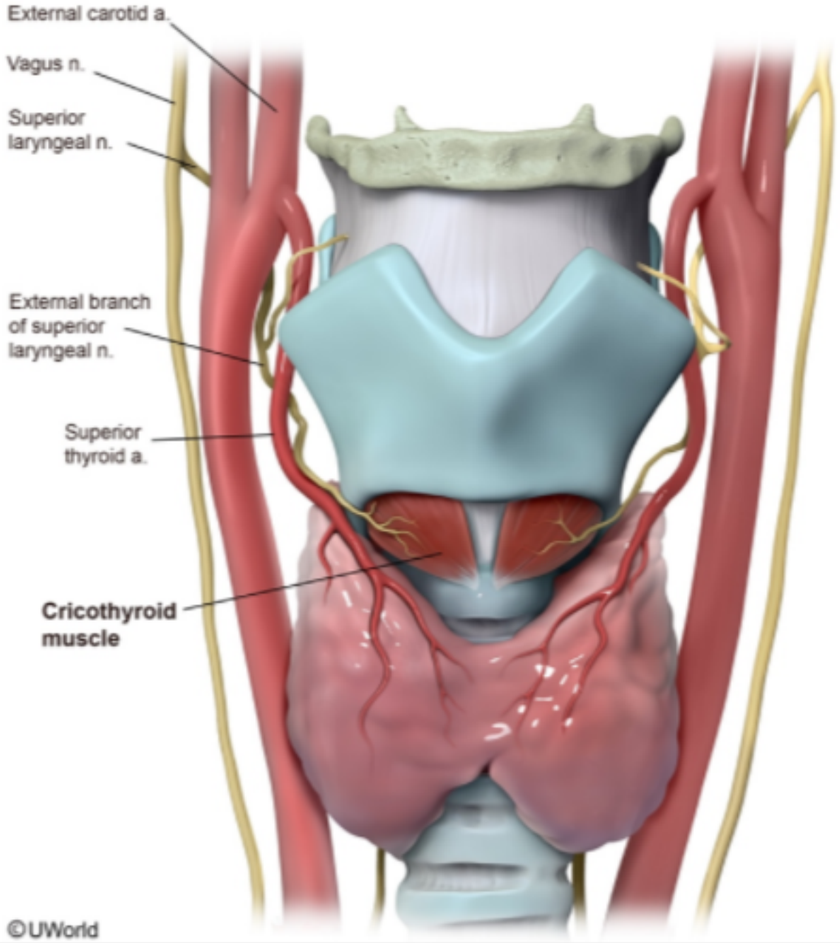

Zoom In | Zoom Out | Reset | Add To New Card | Existing Card

Exhibit Display

Cranial nerve reflexes

Reflex	Effect	Afferent	Efferent
Pupillary light reflex	Light-induced pupil constriction	II	III
Corneal reflex	Corneal stimulation causes orbicularis oculi to contract eyelids	V1 (ophthalmic branch)	VII
Jaw-jerk reflex	Stretch reflex stimulating masseter contraction	V3 (sensory from muscle spindles)	V3
Vestibulo-ocular reflex	Compensatory eye movements that provide image stabilization when head/body moves	VIII (vestibular component)	III, IV, VI
Carotid sinus reflex	Increased carotid sinus pressure causes decreased heart rate & blood pressure	IX	X (sympathetic tone also inhibited)
Cough reflex	Cough induced by upper respiratory tract irritation	X	X
Gag reflex	Reflex contraction of the pharyngeal constrictor muscles evoked by touching the back of the throat	IX	X

©UWorld

Zoom In | Zoom Out | Reset | Add To New Card | Existing Card

1
2
3
4
5
6
7
8
9
10
11
12
13
14
15
16
17
18
19
20
21
22
23
24

A 26-year-old woman comes to the office due to pain in her right jaw that is deep, achy, and worse in the morning. It radiates to her temple and is associated with headaches. The patient also has neck pain and stiffness, especially on the right side. When she chews, she hears a clicking noise in her right ear. The patient is in a competitive graduate study program and has been under significant stress. Her roommate says that she has been grinding her teeth at night. Physical examination will likely reveal spasms of which of the following muscles?

A. Buccinator
B. Levator veli palatini
C. Masseter
D. Mylohyoid
E. Omohyoid

Submit

A 26-year-old woman comes to the office due to pain in her right jaw that is deep, achy, and worse in the morning. It radiates to her temple and is associated with headaches. The patient also has neck pain and stiffness, especially on the right side. When she chews, she hears a clicking noise in her right ear. The patient is in a competitive graduate study program and has been under significant stress. Her roommate says that she has been grinding her teeth at night. Physical examination will likely reveal spasms of which of the following muscles?

- A. Buccinator (6%)
- B. Levator veli palatini (2%)
- ✓ C. Masseter (89%)
- D. Mylohyoid (1%)
- E. Omohyoid (0%)

Omitted
Correct answer
C

89%
Answered correctly

02 secs
Time Spent

05/11/2020
Last Updated

Explanation

This patient has jaw pain, a clicking noise when she chews, and associated headaches and neck stiffness, which is suggestive of **temporomandibular joint (TMJ) syndrome**. The underlying etiology of TMJ syndrome is multifactorial and includes TMJ derangement (eg, jaw misalignment, trauma), and hypersensitivity of the mandibular nerve (CN V3). **Mechanical derangement** of the TMJ can result in irritation and hypersensitivity of CN V3, leading to pathologic contraction of the **masseter** and **pterygoid** muscles (which worsens jaw pain and dysfunction). **Spasms** of these muscles can sometimes be palpated along the mandibular ramus.

Repetitive jaw motions (eg, gum chewing, teeth grinding) are thought to contribute to the development of TMJ syndrome due to increased

This patient has jaw pain, a clicking noise when she chews, and associated headaches and neck stiffness, which is suggestive of **temporomandibular joint (TMJ) syndrome**. The underlying etiology of TMJ syndrome is multifactorial and includes TMJ derangement (eg, jaw misalignment, trauma), and hypersensitivity of the mandibular nerve (CN V3). **Mechanical derangement** of the TMJ can result in irritation and hypersensitivity of CN V3, leading to pathologic contraction of the **masseter** and **pterygoid** muscles (which worsens jaw pain and dysfunction). **Spasms** of these muscles can sometimes be palpated along the mandibular ramus.

Repetitive jaw motions (eg, gum chewing, teeth grinding) are thought to contribute to the development of TMJ syndrome due to increased workload and strain on the joint. Similar to some other musculoskeletal pain disorders (eg, tension headache), TMJ pain also seems to be related to psychiatric conditions and emotional distress.

(Choice A) The buccinator muscle underlies the cheek and holds it close to the teeth to control the food bolus when chewing. It is innervated by a branch of the facial nerve (CN VII).

(Choice B) The levator veli palatini elevates the soft palate during swallowing to prevent food from refluxing into the nasopharynx. It is innervated by the pharyngeal branch of the vagus nerve (CN X).

(Choice D) The mylohyoid runs from the mandible to the hyoid bone, forming the floor of mouth. Although it is innervated by a branch of CN V3, it does not help close the jaw. It acts during swallowing to elevate the tongue and hyoid bone, which propels the food bolus into the posterior oral cavity and oropharynx.

(Choice E) The omohyoid muscle travels from the hyoid bone to the clavicle and helps depress the hyoid during speech or swallowing. It is innervated by the ansa cervicalis, a branch of the cervical plexus.

Educational objective:
Temporomandibular joint disorder is associated with dysfunction of the temporomandibular joint and hypersensitivity of the mandibular nerve (CN V3). This can result in pathologic contraction of the muscles of mastication, including the masseter and pterygoids.

References

- Temporomandibular disorders.
- Depression, pain, exposure to stressful life events, and long-term outcomes in temporomandibular disorder patients.

1
2
3
4
5
6
7
8
9
10
11
12
13
14
15
16
17
18
19
20
21
22
23
24

A 30-year-old man comes to the emergency department due to left eye pain after being involved in a street fight. He received a fist blow to the left eye and has since had pain and diplopia. Past medical history is notable for 2 previous gunshot wounds. The patient does not smoke cigarettes but has a history of heavy alcohol intake and frequent marijuana use. On examination, there is significant soft tissue swelling around the left eye. Visual acuity is normal, but extraocular motility of the left eye is limited. Pupillary reflexes are normal. Coronal CT scan of the orbits is shown in the image below.

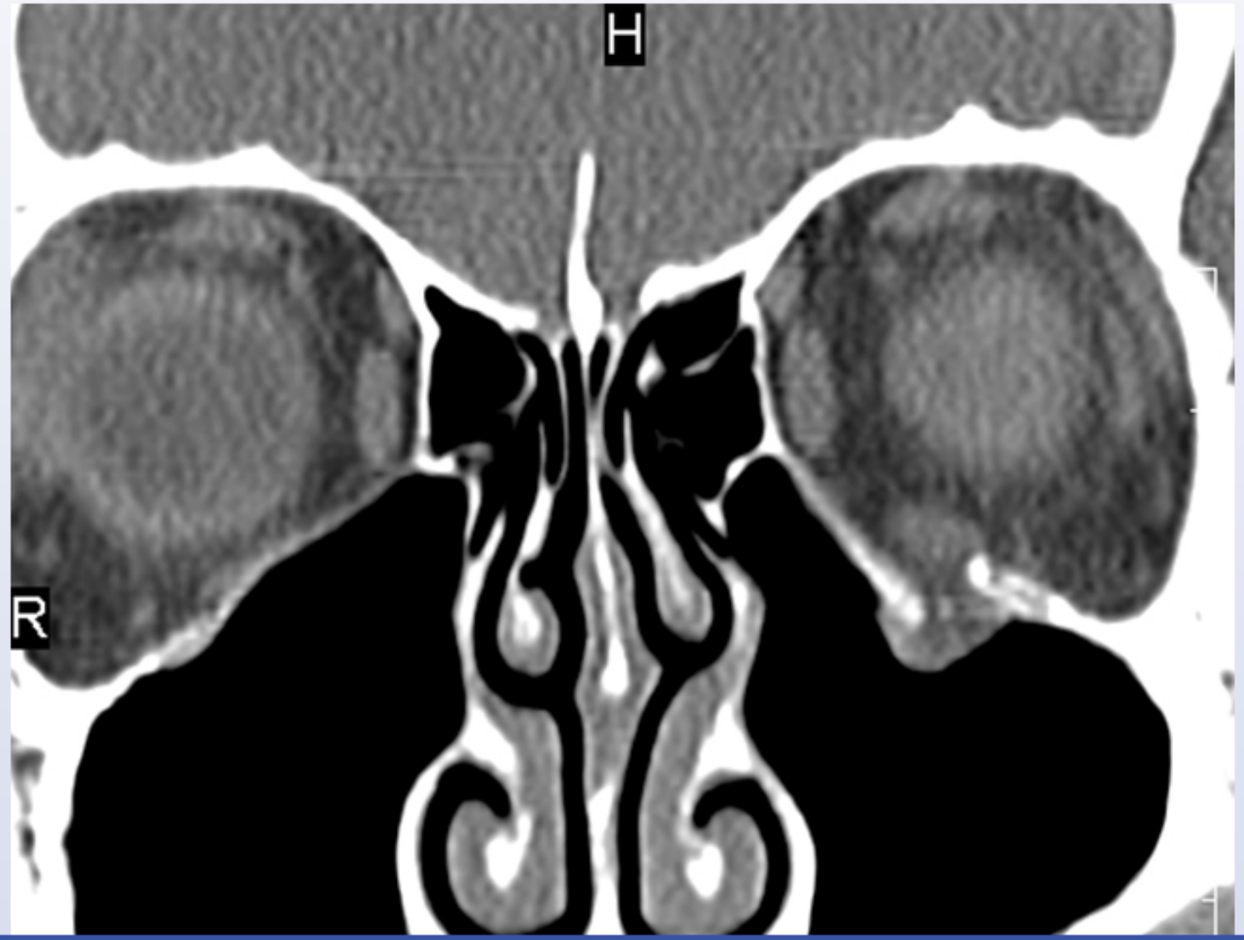

1
2
3
4
5
6
7
8
9
10
11
12
13
14
15
16
17
18
19
20
21
22
23
24

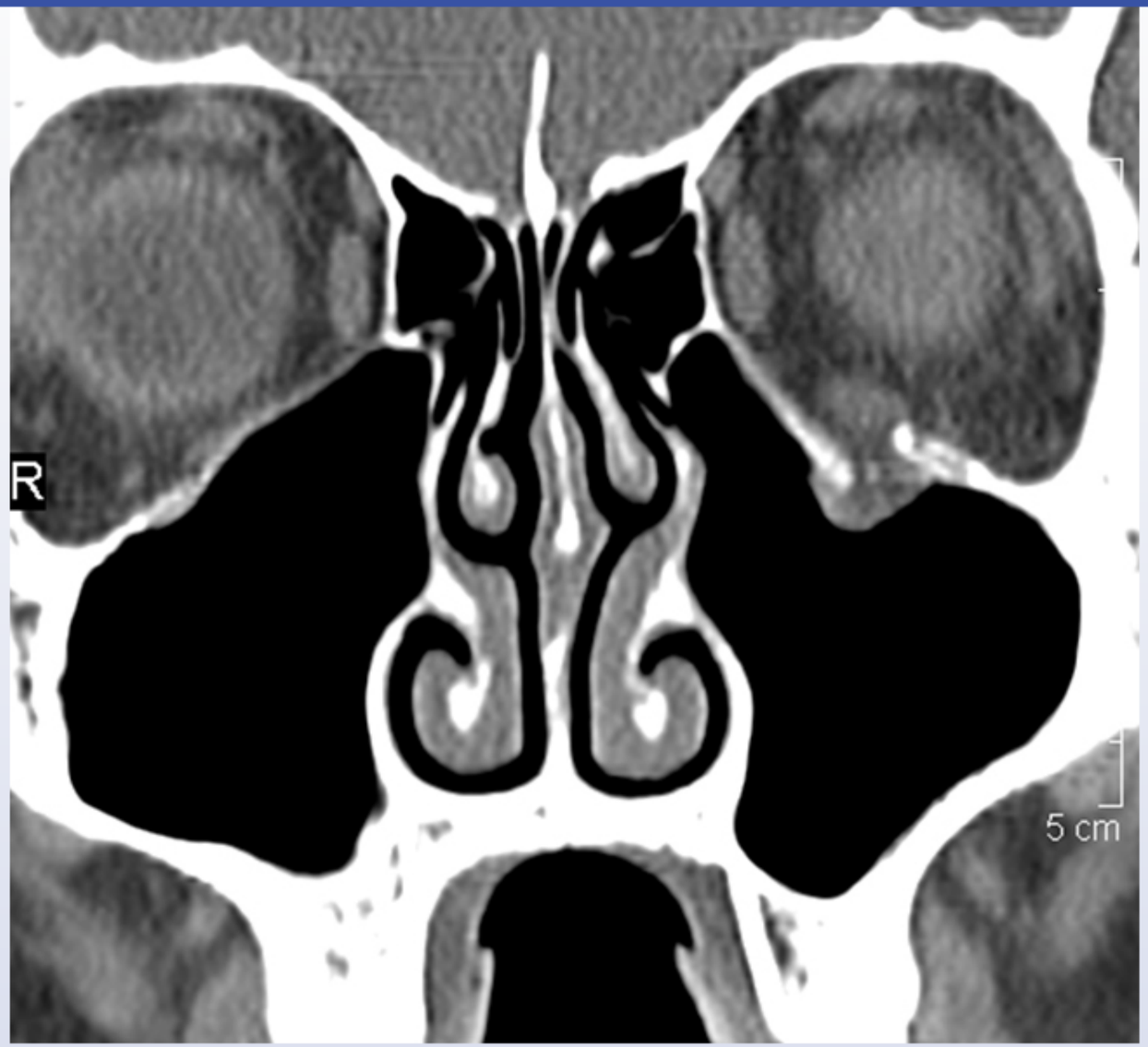

The orbital contents of this patient are most likely to herniate into which of the following sites?

1
2
3
4
5
6
7
8
9
10
11
12
13
14
15
16
17
18
19
20
21
22
23
24

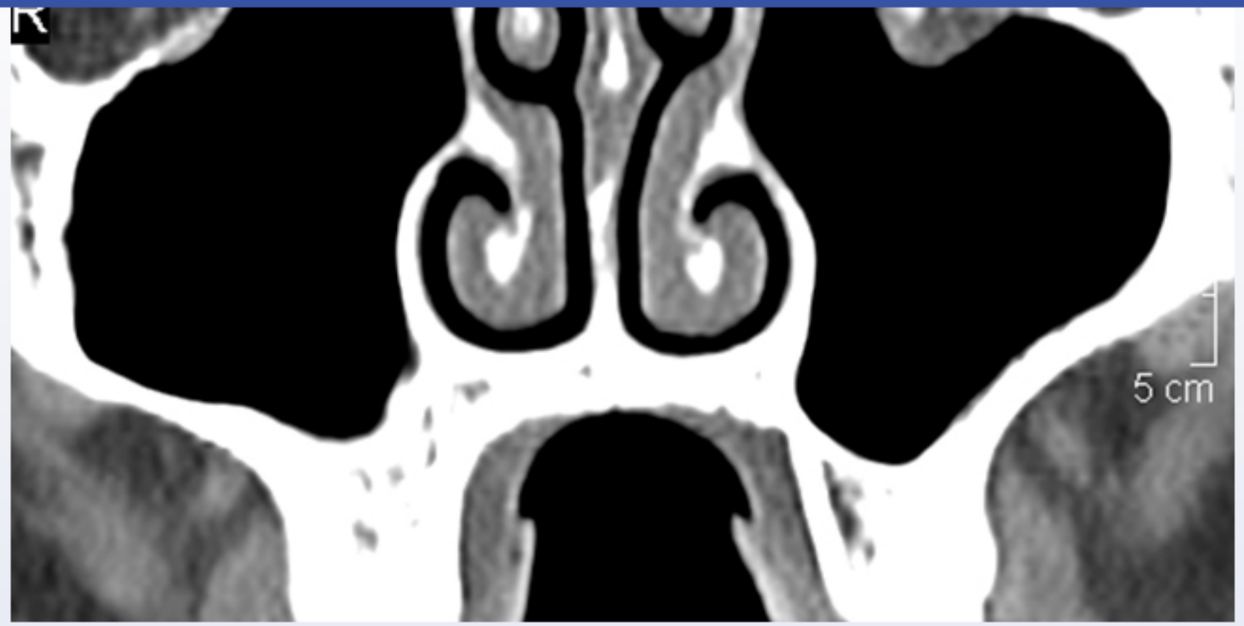

The orbital contents of this patient are most likely to herniate into which of the following sites?

- A. Ethmoid cells
- B. Frontal sinus
- C. Inferior conchae
- D. Maxillary sinus
- E. Sphenoid sinus

Submit

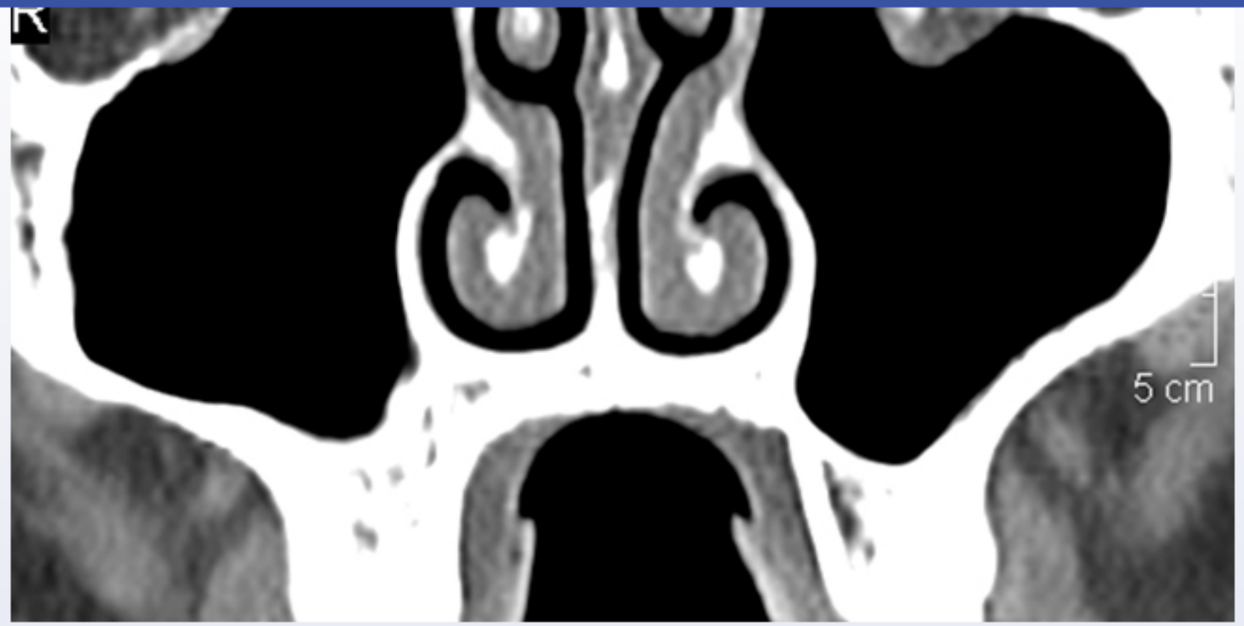

The orbital contents of this patient are most likely to herniate into which of the following sites?

- A. Ethmoid cells (4%)
- B. Frontal sinus (2%)
- C. Inferior conchae (0%)
- ✓ D. Maxillary sinus (85%)
- E. Sphenoid sinus (6%)

Omitted
Correct answer

85%
Answered correctly

08 secs
Time Spent

05/05/2020
Last Updated

Omitted
Correct answer
D

85%
Answered correctly

08 secs
Time Spent

05/05/2020
Last Updated

Explanation

The orbit is bound superiorly by the thick orbital plate of the frontal bone and laterally by the thick bone of the zygoma and greater and lesser sphenoid wings. In contrast, the **orbital floor** is composed of a very thin layer of bone that separates the orbit from the air-filled **maxillary sinus**. Similarly, the orbit's medial wall is composed of the thin ethmoid and lacrimal bones, which separate it from the ethmoid air cells.

Blunt trauma to the eye causes a rapid increase in pressure that typically does not rupture the globe but is transmitted posteriorly into the orbit. The weakest plates of bone in the orbit, the medial and inferior walls, are common sites of fracture. Fracture is typically evident on radiographic imaging, and fluid (eg, blood) or herniation of the orbital contents can often be visualized in the adjacent normally air-filled sinuses.

(Choice A) The ethmoid air cells are medial to the orbit. They are unaffected in this patient, but they can be affected in blowout fractures of the orbit's medial wall.

(Choice B) The frontal sinus is not pictured above. It lies in the medial part of the supraorbital frontal bone.

(Choice C) The inferior nasal conchae form part of the nasal turbinate system. They are not air-filled sinuses.

(Choice E) The sphenoid sinuses (not pictured above) lie anterior to the optic chiasm and are not in close relation to the orbit.

Educational objective:
Blunt trauma to the globe can cause orbital blowout fractures. These fractures most commonly involve the medial or inferior orbital walls due to the thin bone bordering the ethmoid and maxillary sinuses.

Anatomy	Ear, Nose & Throat (ENT)	Orbital fracture
Subject	System	Topic

Copyright © UWorld. All rights reserved.

Correct answer | 85% | 08 secs | 05/05/2020

Exhibit Display

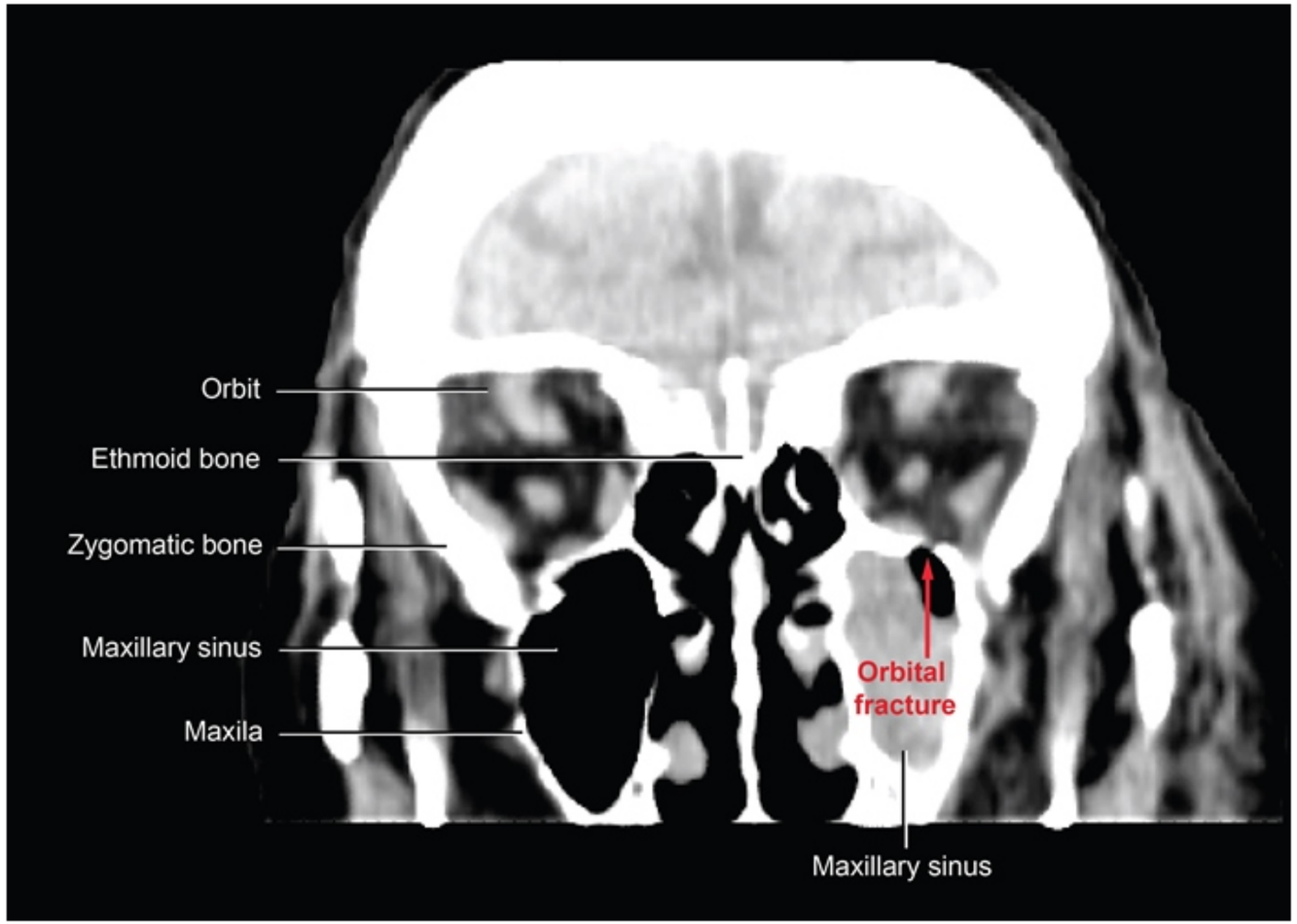

Zoom In | Zoom Out | Reset | Add To New Card | Existing Card

A 73-year-old woman comes to the physician complaining of progressive, severe pain and discharge from her left ear for the past 2 days. She has had type 2 diabetes for many years and has been noncompliant with her medications and follow-up appointments. On examination, moving or touching the pinna produces extreme pain. Otoscopic examination shows granulation tissue in the left ear canal with a scant amount of discharge. The tympanic membrane is clear, and there is no middle ear effusion. Initial cultures from the ear show a Gram-negative rod. Which of the following microbiological characteristics best describes the infecting organism?

A. Comma-shaped and grows well in high pH

B. Fast lactose fermenter

C. Motile and oxidase positive

D. Nonmotile and a lactose nonfermenter

E. Requires factors V and X for growth

Submit

A 73-year-old woman comes to the physician complaining of progressive, severe pain and discharge from her left ear for the past 2 days. She has had type 2 diabetes for many years and has been noncompliant with her medications and follow-up appointments. On examination, moving or touching the pinna produces extreme pain. Otoscopic examination shows granulation tissue in the left ear canal with a scant amount of discharge. The tympanic membrane is clear, and there is no middle ear effusion. Initial cultures from the ear show a Gram-negative rod. Which of the following microbiological characteristics best describes the infecting organism?

A. Comma-shaped and grows well in high pH (2%)

B. Fast lactose fermenter (6%)

✓ C. Motile and oxidase positive (42%)

D. Nonmotile and a lactose nonfermenter (25%)

E. Requires factors V and X for growth (22%)

Omitted
Correct answer
C

42%
Answered correctly

01 sec
Time Spent

06/07/2020
Last Updated

Explanation

Distinguishing characteristics of Pseudomonas aeruginosa infections	
	• Pneumonia (especially in cystic fibrosis

Distinguishing characteristics of Pseudomonas aeruginosa infections	
Types of infections	• Pneumonia (especially in cystic fibrosis and ventilated patients) • Life-threatening infections in neutropenic and burn patients • Otitis externa (particularly malignant) • Hot tub folliculitis • Ecthyma gangrenosum
Microbiology	• Motile aerobic Gram-negative rod • Nonlactose-fermenting, oxidase-positive • Produces pyocyanin (blue-green) pigment • Emits a grapelike, fruity odor • Produces endotoxin (fever, shock) and exotoxin A (inactivates EF-2)
Effective antibiotics	• Aminoglycosides (gentamicin, tobramycin, amikacin) • Antipseudomonal penicillins (ticarcillin, piperacillin) • 3rd- and 4th- generation cephalosporins (ceftazidime, cefepime) • Quinolones (ciprofloxacin) • Monobactams (aztreonam)

Effective antibiotics	• Aminoglycosides (gentamicin, tobramycin, amikacin) • Antipseudomonal penicillins (ticarcillin, piperacillin) • 3rd- and 4th- generation cephalosporins (ceftazidime, cefepime) • Quinolones (ciprofloxacin) • Monobactams (aztreonam) • Carbapenems (imipenem, meropenem)

©UWorld

This patient's presentation is consistent with malignant otitis externa (MOE), a severe infection most commonly seen in elderly diabetic patients. It is most frequently caused by *Pseudomonas aeruginosa*, a nonlactose-fermenting, oxidase-positive, motile Gram-negative rod. Patients typically present with exquisite ear pain and drainage. The granulation tissue seen within the ear canal is an important characteristic finding of MOE, and the tympanic membrane is usually intact. Progression of this infection can lead to osteomyelitis of the skull base and cranial nerve damage. Treatment consists of systemic antibiotics such as ciprofloxacin that are effective against *P aeruginosa*.

(Choice A) *Vibrio cholerae* is an oxidase-positive, Gram-negative, comma-shaped rod that can grow on an alkaline medium that kills most organisms. *V cholerae* causes a toxin-mediated (stimulates adenylyl cyclase) watery diarrhea.

(Choice B) Gram-negative rods that are fast lactose fermenters include *Klebsiella* and *Escherichia coli*. They commonly cause urinary tract infections.

(Choice D) *Shigella* is a Gram-negative, nonlactose-fermenting, nonmotile, rod-shaped bacterium. It causes shigellosis, a hemorrhagic diarrheal disease.

(Choice E) *Haemophilus influenza* is Gram-negative, rod-shaped bacterium that requires factor X (hematin) and factor V (NAD+) for growth. Nontypable (unencapsulated) *H influenzae* is a frequent cause of acute otitis media in children and adults. Acute otitis media is associated with an inflamed, erythematous, bulging, immobile tympanic membrane due to the presence of infected fluid in the middle ear.

This patient's presentation is consistent with malignant otitis externa (MOE), a severe infection most commonly seen in elderly diabetic patients. It is most frequently caused by *Pseudomonas aeruginosa*, a nonlactose-fermenting, oxidase-positive, motile Gram-negative rod. Patients typically present with exquisite ear pain and drainage. The granulation tissue seen within the ear canal is an important characteristic finding of MOE, and the tympanic membrane is usually intact. Progression of this infection can lead to osteomyelitis of the skull base and cranial nerve damage. Treatment consists of systemic antibiotics such as ciprofloxacin that are effective against *P aeruginosa*.

(Choice A) *Vibrio cholerae* is an oxidase-positive, Gram-negative, comma-shaped rod that can grow on an alkaline medium that kills most organisms. *V cholerae* causes a toxin-mediated (stimulates adenylyl cyclase) watery diarrhea.

(Choice B) Gram-negative rods that are fast lactose fermenters include *Klebsiella* and *Escherichia coli*. They commonly cause urinary tract infections.

(Choice D) *Shigella* is a Gram-negative, nonlactose-fermenting, nonmotile, rod-shaped bacterium. It causes shigellosis, a hemorrhagic diarrheal disease.

(Choice E) *Haemophilus influenza* is Gram-negative, rod-shaped bacterium that requires factor X (hematin) and factor V (NAD+) for growth. Nontypable (unencapsulated) *H influenzae* is a frequent cause of acute otitis media in children and adults. Acute otitis media is associated with an inflamed, erythematous, bulging, immobile tympanic membrane due to the presence of infected fluid in the middle ear.

Educational objective:
Pseudomonas aeruginosa is a nonlactose-fermenting, oxidase-positive, motile, Gram-negative rod. It is the most common cause of malignant otitis externa (MOE), a serious infection of the ear seen in elderly diabetic patients. MOE presents with exquisite ear pain and drainage, and granulation tissue is often seen within the ear canal.

References

- Malignant otitis externa.

Microbiology	Ear, Nose & Throat (ENT)	Otitis externa
Subject	System	Topic

Copyright © UWorld. All rights reserved.

A 56-year-old previously healthy man comes to the office due to decreased hearing in both ears. He reports difficulty understanding conversations in crowded rooms. His wife adds that they often argue about the volume of the television set. The patient cannot remember precisely when he first noticed hearing loss but says it has been present at least 6 months and is getting worse. For the past 12 years, he has worked in a factory where he has to shout to communicate with coworkers and has seldom worn hearing protection. An audiogram is obtained as shown in the image below.

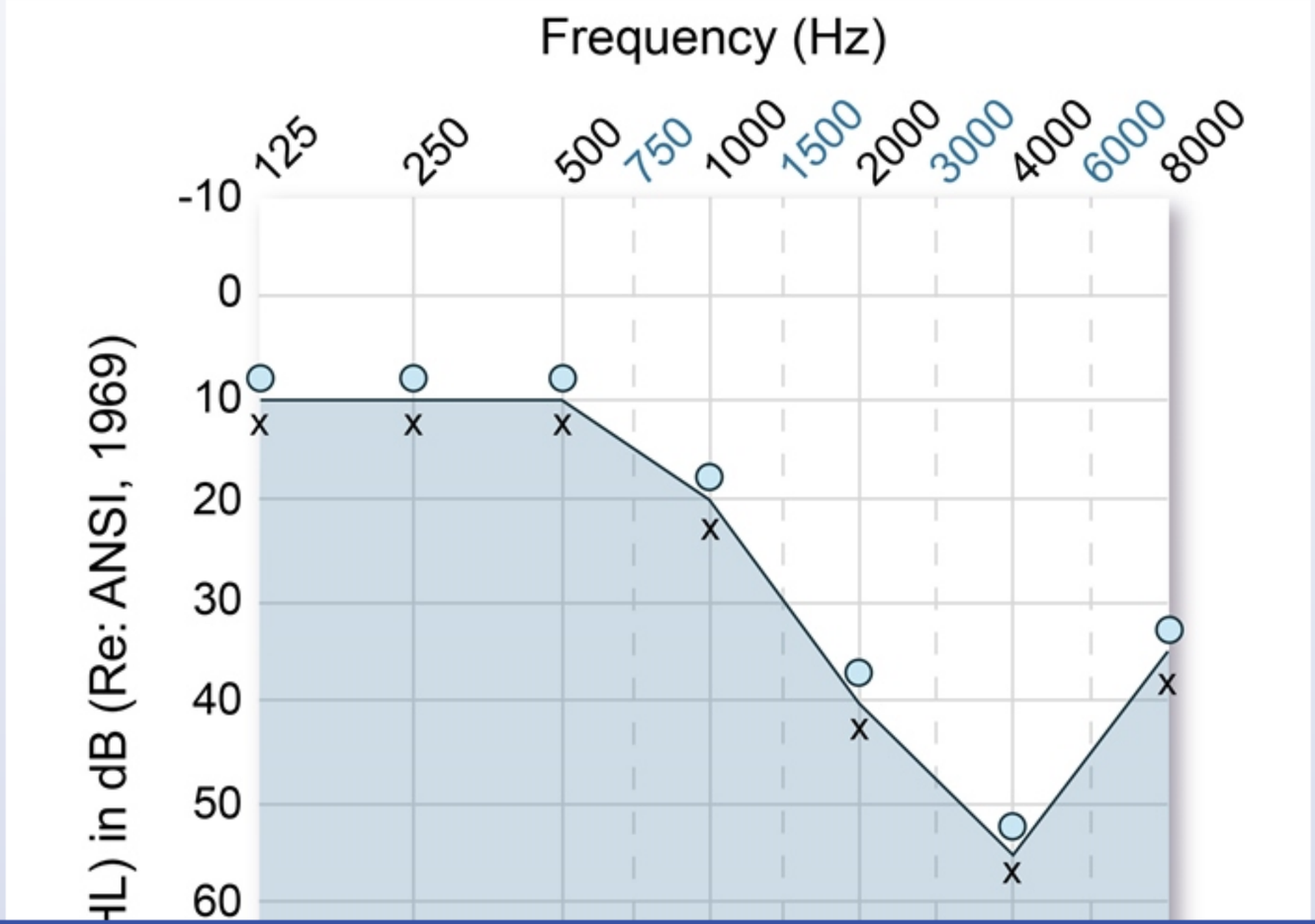

1
2
3
4
5
6
7
8
9
10
11
12
13
14
15
16
17
18
19
20
21
22
23
24

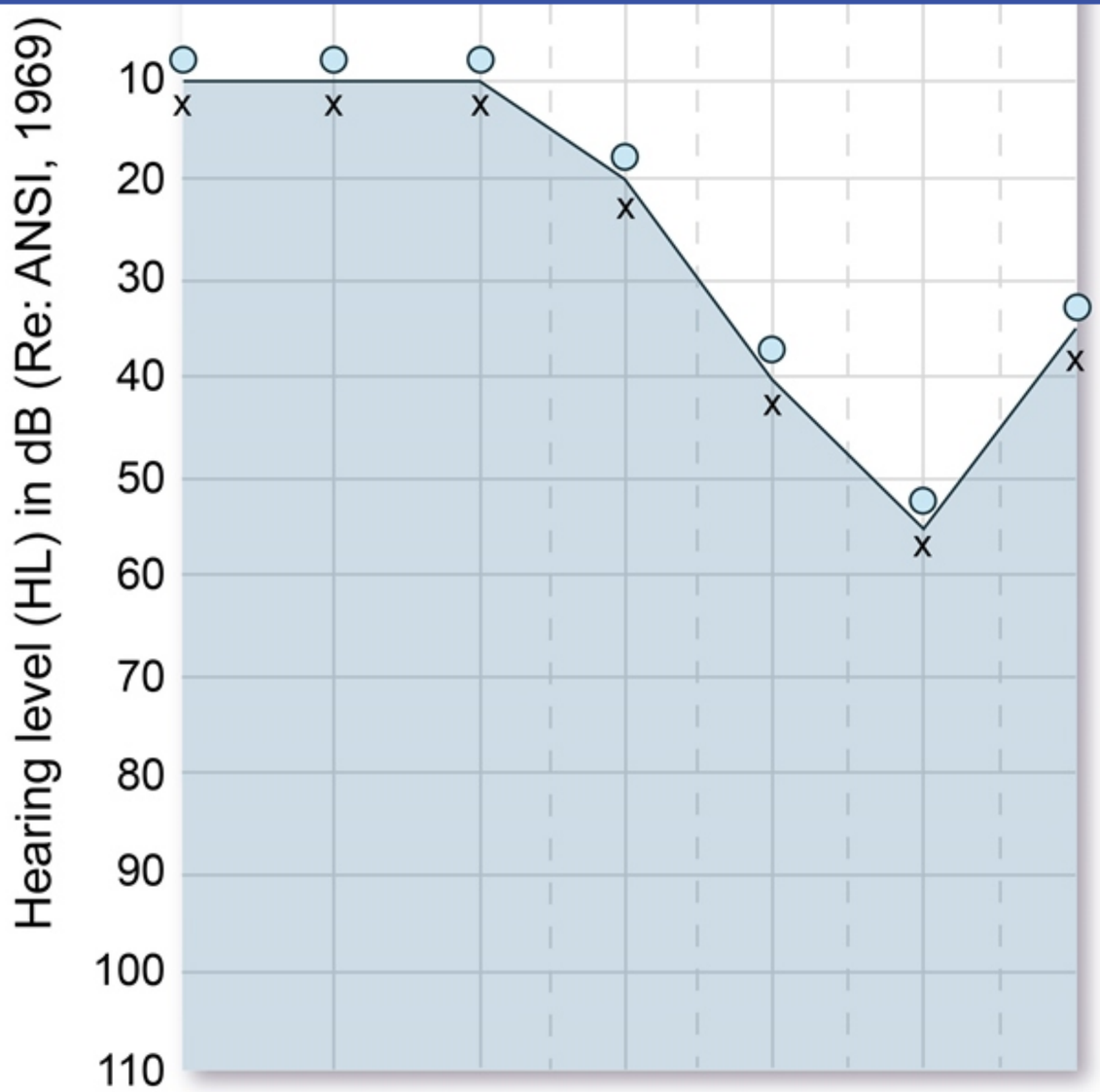

©UWorld

○ Right ear air conduction x Right ear bone conduction

1
2
3
4
5
6
7
8
9
10
11
12
13
14
15
16
17
18
19
20
21
22
23
24

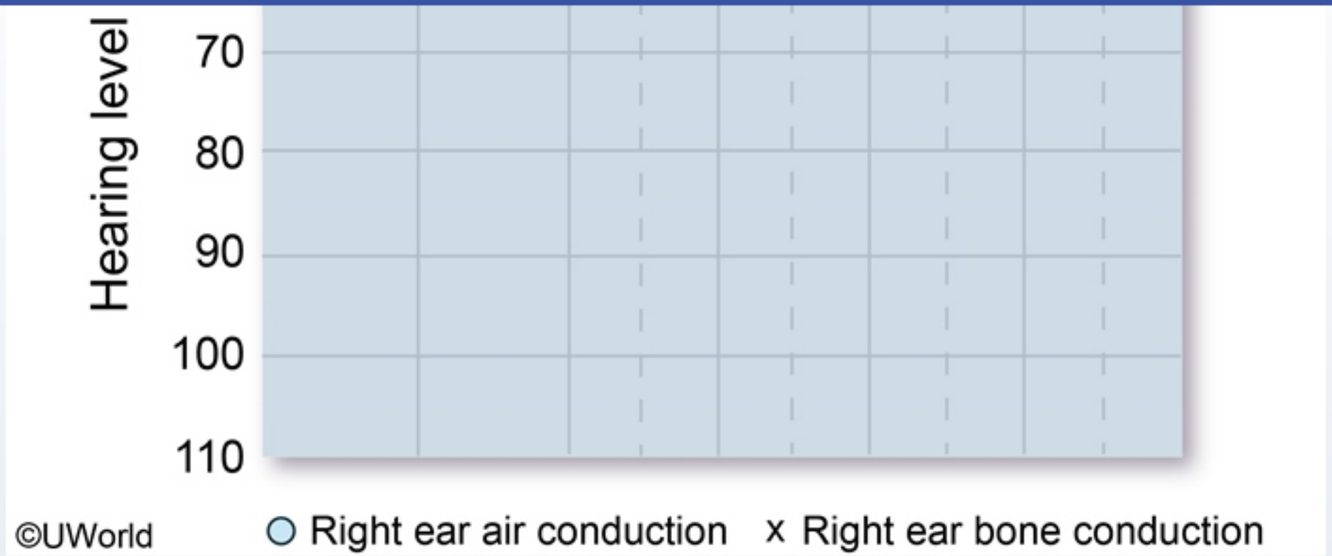

Which of the following is most likely abnormal in this patient?

- A. Auditory nerve
- B. Cochlear cupula
- C. Middle ear ossicles
- D. Organ of Corti
- E. Round window
- F. Tympanic membrane

Submit

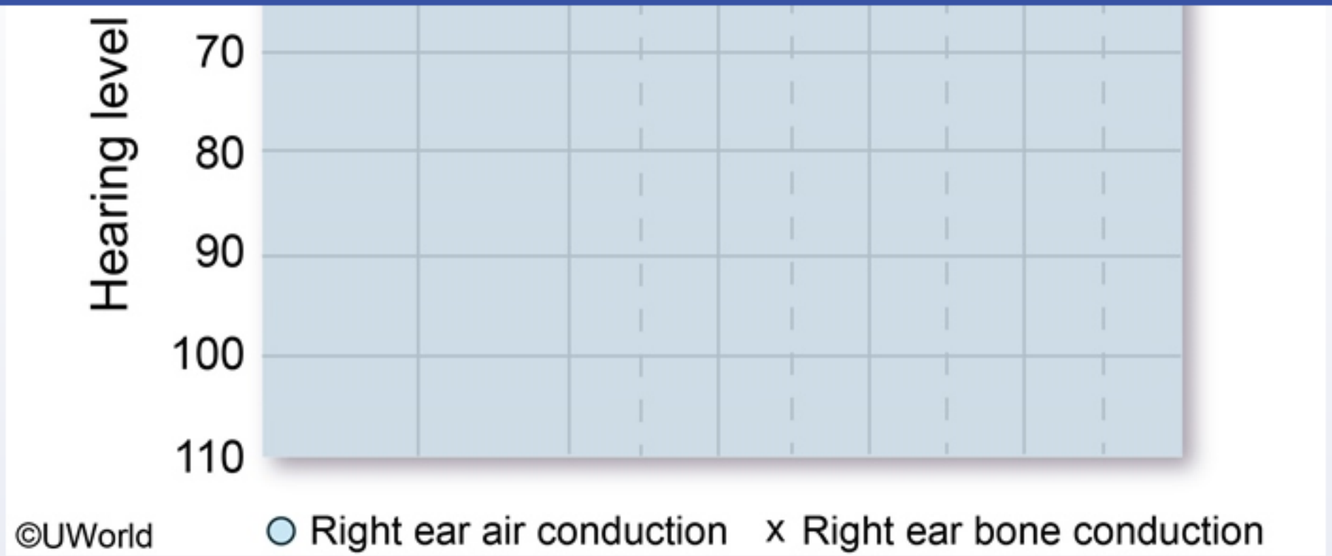

Which of the following is most likely abnormal in this patient?

- A. Auditory nerve (10%)
- B. Cochlear cupula (13%)
- C. Middle ear ossicles (13%)
- ✓ D. Organ of Corti (51%)
- E. Round window (2%)
- F. Tympanic membrane (8%)

Omitted
Correct answer

51%
Answered correctly

07 secs
Time Spent

01/23/2020
Last Updated

1
2
3
4
5
6
7
8
9
10
11
12
13
14
15
16
17
18
19
20
21
22
23
24

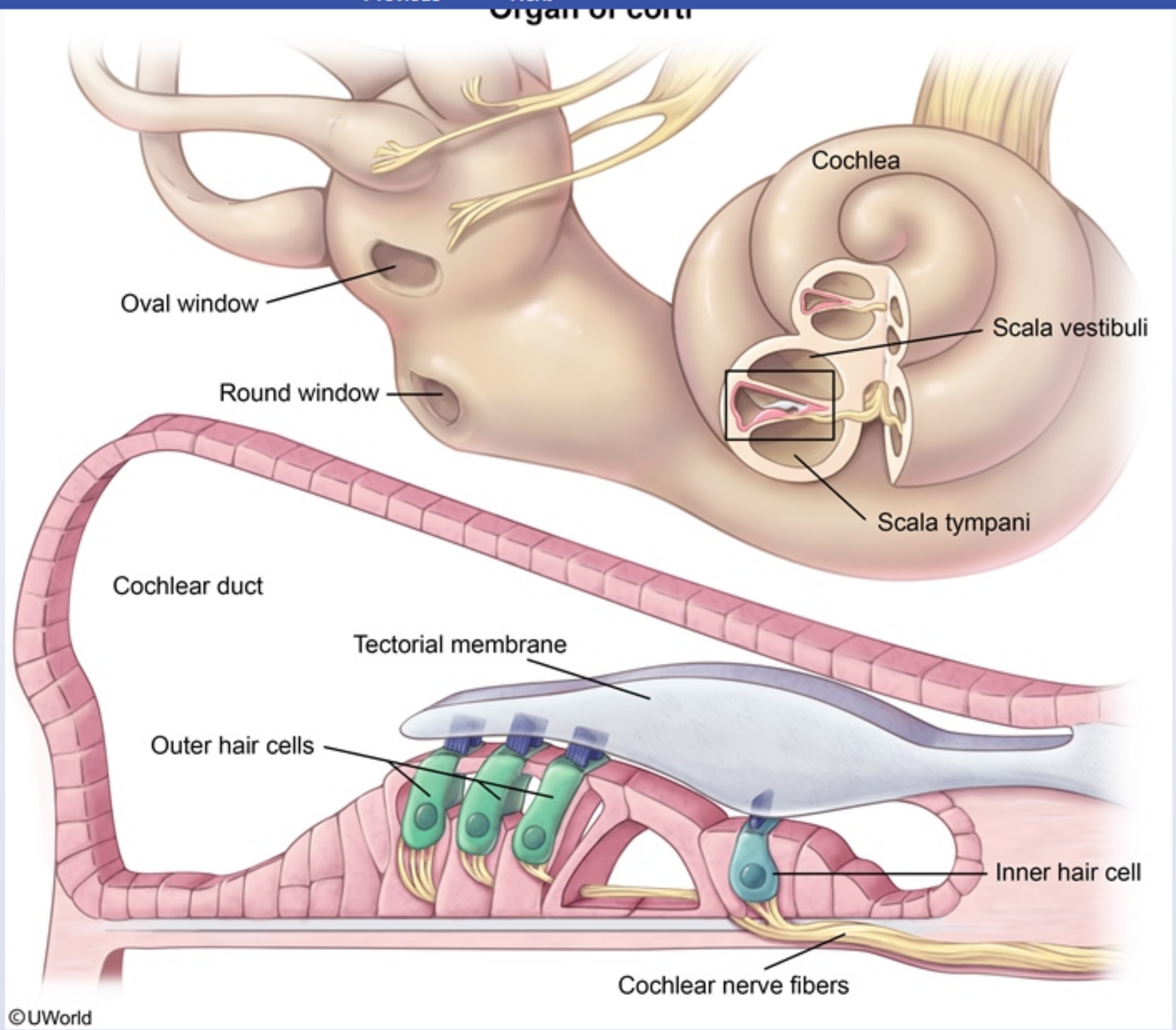

This patient has high-frequency hearing loss due to chronic noise exposure. Transduction of mechanical sound waves into nerve impulses occurs

1
2
3
4
5
6
7
8
9
10
11
12
13
14
15
16
17
18
19
20
21
22
23
24

Organ of corti

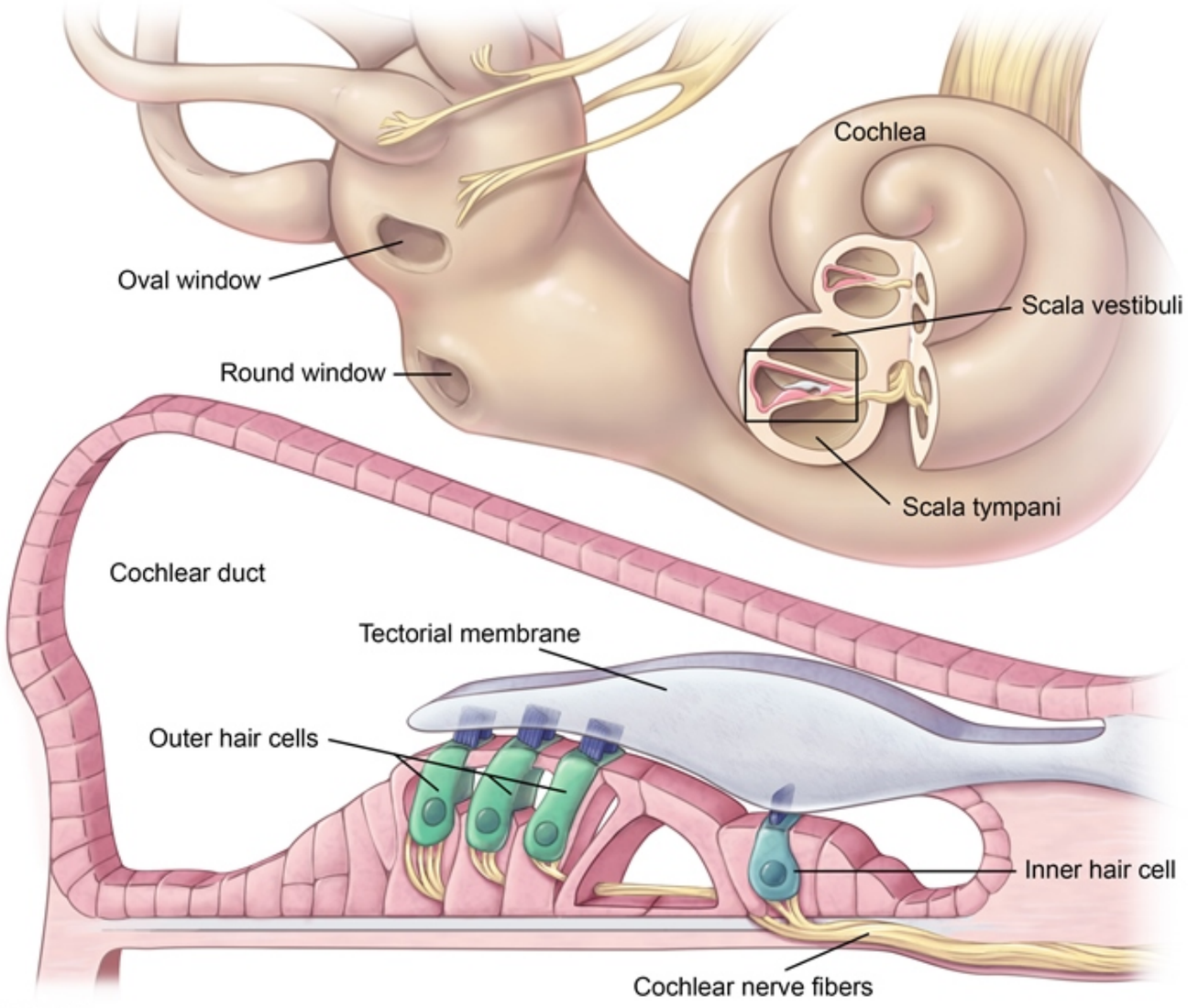

©UWorld

This patient has high-frequency hearing loss due to chronic noise exposure. Transduction of mechanical sound waves into nerve impulses occurs in the **organ of Corti** through the following steps:

1. Sound reaches the middle ear by vibrating the tympanic membrane.
2. The vibration is transferred to the oval window by the ossicles.
3. Vibration of the oval window causes vibration of the basilar membrane, which in turn causes bending of the hair cell cilia against the tectorial membrane.
4. Hair cell bending causes oscillating hyperpolarization and depolarization of the auditory nerve, thereby creating nerve impulses from sound.

Noise-induced hearing loss results from trauma to the **stereociliated hair cells** of the organ of Corti. The acoustic reflex normally dampens the effects of loud noise by causing the stapedius and tensor tympani muscles to contract, which lessens the responsiveness of the ossicles to sound. However, prolonged noise exposure can cause distortion or fracture of the stereocilia due to shearing forces against the tectorial membrane. High-frequency hearing is lost first, regardless of the frequency of the sound causing the damage.

(Choice A) Hearing loss originating in the auditory nerve is most commonly due to a vestibular schwannoma (acoustic neuroma). Patients develop high-frequency sensorineural hearing loss, but symptoms are usually unilateral.

(Choice B) The cochlear cupula is the apex of the cochlea and is distant from the oval window. The distal cochlea primarily registers low-frequency sound.

(Choice C) Defects of the middle ear ossicles (eg, otosclerosis) can cause hearing loss that generally affects air conduction across all frequencies. This patient's hearing loss affects both air and bone conduction.

(Choice E) The round window lies between the middle and inner ear and moves outward when the stapes causes the oval window to move inward. Malformation of the round window can cause congenital hearing impairment, but acquired disorders are rare.

(Choice F) Perforation or rupture of the tympanic membrane can occur with infection, trauma, pressure changes, or sudden and very loud noises. Rupture of the tympanic membrane causes unilateral conductive hearing loss.

Educational objective:
Prolonged exposure to loud noises causes hearing loss due to damage to the stereociliated hair cells of the organ of Corti.

4. Hair cell bending causes oscillating hyperpolarization and depolarization of the auditory nerve, thereby creating nerve impulses from sound.

Noise-induced hearing loss results from trauma to the **stereociliated hair cells** of the organ of Corti. The acoustic reflex normally dampens the effects of loud noise by causing the stapedius and tensor tympani muscles to contract, which lessens the responsiveness of the ossicles to sound. However, prolonged noise exposure can cause distortion or fracture of the stereocilia due to shearing forces against the tectorial membrane. High-frequency hearing is lost first, regardless of the frequency of the sound causing the damage.

(Choice A) Hearing loss originating in the auditory nerve is most commonly due to a vestibular schwannoma (acoustic neuroma). Patients develop high-frequency sensorineural hearing loss, but symptoms are usually unilateral.

(Choice B) The cochlear cupula is the apex of the cochlea and is distant from the oval window. The distal cochlea primarily registers low-frequency sound.

(Choice C) Defects of the middle ear ossicles (eg, otosclerosis) can cause hearing loss that generally affects air conduction across all frequencies. This patient's hearing loss affects both air and bone conduction.

(Choice E) The round window lies between the middle and inner ear and moves outward when the stapes causes the oval window to move inward. Malformation of the round window can cause congenital hearing impairment, but acquired disorders are rare.

(Choice F) Perforation or rupture of the tympanic membrane can occur with infection, trauma, pressure changes, or sudden and very loud noises. Rupture of the tympanic membrane causes unilateral conductive hearing loss.

Educational objective:
Prolonged exposure to loud noises causes hearing loss due to damage to the stereociliated hair cells of the organ of Corti.

References

- Hearing impairments caused by genetic and environmental factors.

Anatomy	Ear, Nose & Throat (ENT)	Hearing loss
Subject	System	Topic

Copyright © UWorld. All rights reserved.

1
2
3
4
5
6
7
8
9
10
11
12
13
14
15
16
17
18
19
20
21
22
23
24

A 7-year-old girl is brought to the clinic due to nasal congestion with facial pain. The patient first developed congestion over a year ago. Her parents have been treating it with over-the-counter allergy medications, but there has been no improvement. Over the past 4 months, the congestion has worsened, and now the patient has difficulty breathing through her nose. She also developed a dry cough and a constant, dull pain over her cheeks. The patient's stools have been loose. Temperature is 37.8 C (100 F). Weight is at <1st percentile at 18 kg (39.7 lb), decreased from 19 kg (41.9 lb) 3 months ago. Examination reveals copious yellow mucus within both nares. Translucent, gray, shiny masses obscure the middle turbinates bilaterally. Lymphadenopathy is not present. The lungs have coarse breath sounds bilaterally. The abdomen is soft with no organomegaly. Which of the following is the most likely diagnosis?

A. Cystic fibrosis
B. HIV infection
C. Nasopharyngeal carcinoma
D. Primary ciliary dyskinesia
E. Seasonal allergic rhinitis

Submit

A 7-year-old girl is brought to the clinic due to nasal congestion with facial pain. The patient first developed congestion over a year ago. Her parents have been treating it with over-the-counter allergy medications, but there has been no improvement. Over the past 4 months, the congestion has worsened, and now the patient has difficulty breathing through her nose. She also developed a dry cough and a constant, dull pain over her cheeks. The patient's stools have been loose. Temperature is 37.8 C (100 F). Weight is at <1st percentile at 18 kg (39.7 lb), decreased from 19 kg (41.9 lb) 3 months ago. Examination reveals copious yellow mucus within both nares. Translucent, gray, shiny masses obscure the middle turbinates bilaterally. Lymphadenopathy is not present. The lungs have coarse breath sounds bilaterally. The abdomen is soft with no organomegaly. Which of the following is the most likely diagnosis?

- ✓ A. Cystic fibrosis (73%)
- B. HIV infection (0%)
- C. Nasopharyngeal carcinoma (7%)
- D. Primary ciliary dyskinesia (15%)
- E. Seasonal allergic rhinitis (3%)

Omitted
Correct answer
A

Collecting Statistics

02 secs
Time Spent

07/09/2020
Last Updated

Explanation

Cystic fibrosis features

Cystic fibrosis features

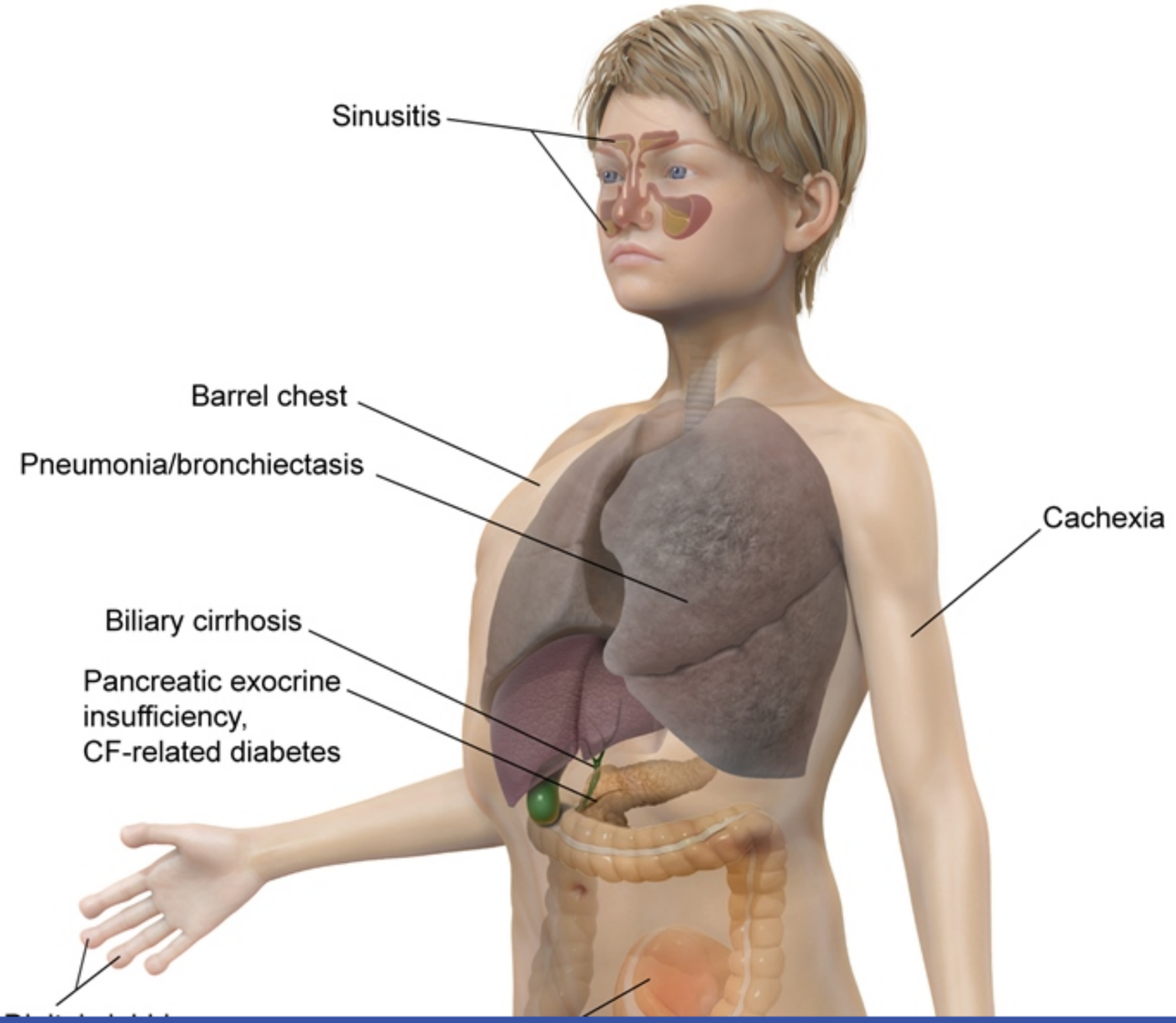

1
2
3
4
5
6
7
8
9
10
11
12
13
14
15
16
17
18
19
20
21
22
23
24

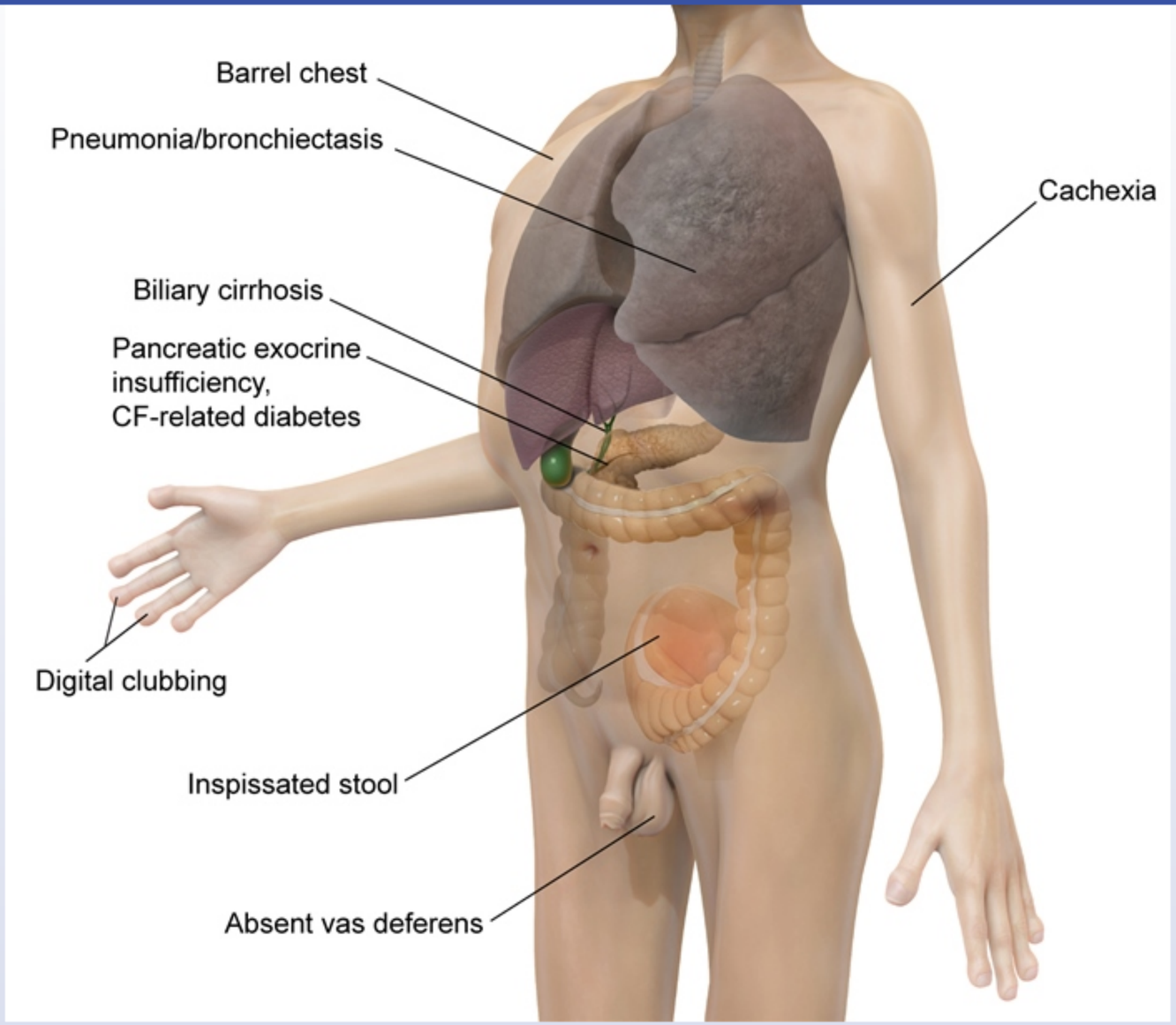

This patient has chronic rhinosinusitis with nasal polyposis and failure to thrive, findings concerning for **cystic fibrosis** (CF). CF is an inherited,

This patient has chronic rhinosinusitis with nasal polyposis and failure to thrive, findings concerning for **cystic fibrosis** (CF). CF is an inherited, multisystem disorder characterized by the abnormal transport of sodium and chloride due to a mutation in the *CFTR* gene. Although common CF mutations (eg, ΔF508) are often identified on newborn screening, less common mutations may go undetected and cause milder symptoms later in childhood.

Abnormal CFTR function causes thick, viscous respiratory secretions and impaired mucociliary clearance, leading to chronic sinopulmonary disease (eg, **chronic rhinosinusitis**). Patients typically have chronic cough, nasal congestion, and facial pain, as seen in this patient. Bilateral **nasal polyps**, benign outgrowths of inflamed mucosa, are also common due to chronic infection and present as nontender, shiny, gray masses in the nasal cavity or paranasal sinuses.

In CF, viscous secretions can also block pancreatic ducts, leading to **pancreatic insufficiency**. Decreased or absent pancreatic enzymes cause fat malabsorption with oily, **loose stools** and **failure to thrive** and/or **weight loss**. Over time, pancreatic injury can also lead to insufficient insulin production and CF-related diabetes.

(Choice B) HIV infection causes chronic infections and weight loss. However, without a known exposure (eg, blood transfusion), most pediatric HIV cases are transmitted perinatally; these patients typically develop symptoms by age 2, unlike this patient, who is age 7. In addition, nasal polyposis is rare with HIV.

(Choice C) Nasopharyngeal carcinoma presents with a nasopharyngeal mass that may cause facial pain and associated weight loss. However, the tumor is typically unilateral, and the diagnosis is usually in patients age >50.

(Choice D) Primary ciliary dyskinesia can present similarly to CF, with chronic rhinosinusitis and nasal polyposis due to impaired mucociliary clearance. However, failure to thrive and weight loss are not associated with this disorder.

(Choice E) Seasonal allergic rhinitis is a risk factor for developing sinus infections and nasal polyposis but would not cause weight loss.

Educational objective:
Chronic rhinosinusitis with nasal polyposis in children should prompt evaluation for cystic fibrosis, especially when signs of pancreatic insufficiency (eg, loose stools, failure to thrive, weight loss) are present.

References

- Paediatric nasal polyps in cystic fibrosis

disease (eg, **chronic rhinosinusitis**). Patients typically have chronic cough, nasal congestion, and facial pain, as seen in this patient. Bilateral **nasal polyps**, benign outgrowths of inflamed mucosa, are also common due to chronic infection and present as nontender, shiny, gray masses in the nasal cavity or paranasal sinuses.

In CF, viscous secretions can also block pancreatic ducts, leading to **pancreatic insufficiency**. Decreased or absent pancreatic enzymes cause fat malabsorption with oily, **loose stools** and **failure to thrive** and/or **weight loss**. Over time, pancreatic injury can also lead to insufficient insulin production and CF-related diabetes.

(Choice B) HIV infection causes chronic infections and weight loss. However, without a known exposure (eg, blood transfusion), most pediatric HIV cases are transmitted perinatally; these patients typically develop symptoms by age 2, unlike this patient, who is age 7. In addition, nasal polyposis is rare with HIV.

(Choice C) Nasopharyngeal carcinoma presents with a nasopharyngeal mass that may cause facial pain and associated weight loss. However, the tumor is typically unilateral, and the diagnosis is usually in patients age >50.

(Choice D) Primary ciliary dyskinesia can present similarly to CF, with chronic rhinosinusitis and nasal polyposis due to impaired mucociliary clearance. However, failure to thrive and weight loss are not associated with this disorder.

(Choice E) Seasonal allergic rhinitis is a risk factor for developing sinus infections and nasal polyposis but would not cause weight loss.

Educational objective:
Chronic rhinosinusitis with nasal polyposis in children should prompt evaluation for cystic fibrosis, especially when signs of pancreatic insufficiency (eg, loose stools, failure to thrive, weight loss) are present.

References

- Paediatric nasal polyps in cystic fibrosis.

Pathophysiology	Ear, Nose & Throat (ENT)	Cystic fibrosis
Subject	System	Topic

Copyright © UWorld. All rights reserved.

A 6-year-old boy is brought to the emergency department by his parents due to persistent nasal bleeding. The boy picks his nose frequently and has had several nosebleeds in the past, all of which stopped spontaneously after pinching the nose. The parents say that they have been pinching the nasal alae for over 30 minutes while the boy leans forward. Family history is negative for bleeding disorders. The patient takes no medications and has no allergies. Examination shows continuous blood trickle from his right nostril. Silver nitrate cautery is performed and the bleeding stops. Cautery was most likely applied to which of the following locations in this patient's nasal cavity?

A. Inferior turbinate

B. Middle meatus

C. Nasal septum

D. Posterior choanae

E. Posterolateral wall

Submit

A 6-year-old boy is brought to the emergency department by his parents due to persistent nasal bleeding. The boy picks his nose frequently and has had several nosebleeds in the past, all of which stopped spontaneously after pinching the nose. The parents say that they have been pinching the nasal alae for over 30 minutes while the boy leans forward. Family history is negative for bleeding disorders. The patient takes no medications and has no allergies. Examination shows continuous blood trickle from his right nostril. Silver nitrate cautery is performed and the bleeding stops. Cautery was most likely applied to which of the following locations in this patient's nasal cavity?

- A. Inferior turbinate (12%)
- B. Middle meatus (10%)
- ✓ C. Nasal septum (45%)
- D. Posterior choanae (10%)
- E. Posterolateral wall (21%)

Omitted
Correct answer
C

45%
Answered correctly

02 secs
Time Spent

05/16/2020
Last Updated

Explanation

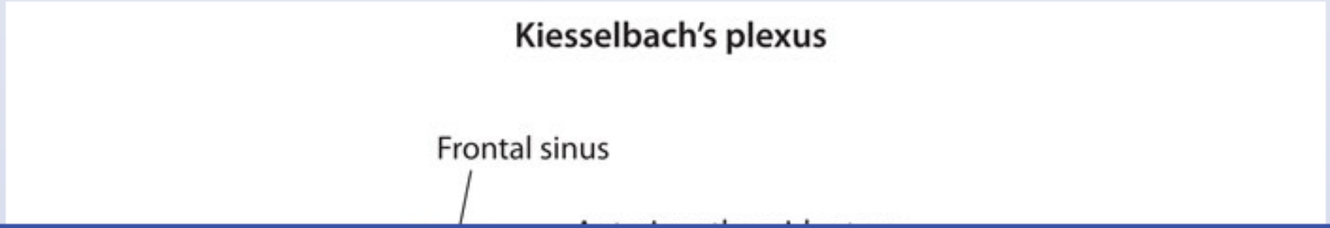

1
2
3
4
5
6
7
8
9
10
11
12
13
14
15
16
17
18
19
20
21
22
23
24

Kiesselbach's plexus

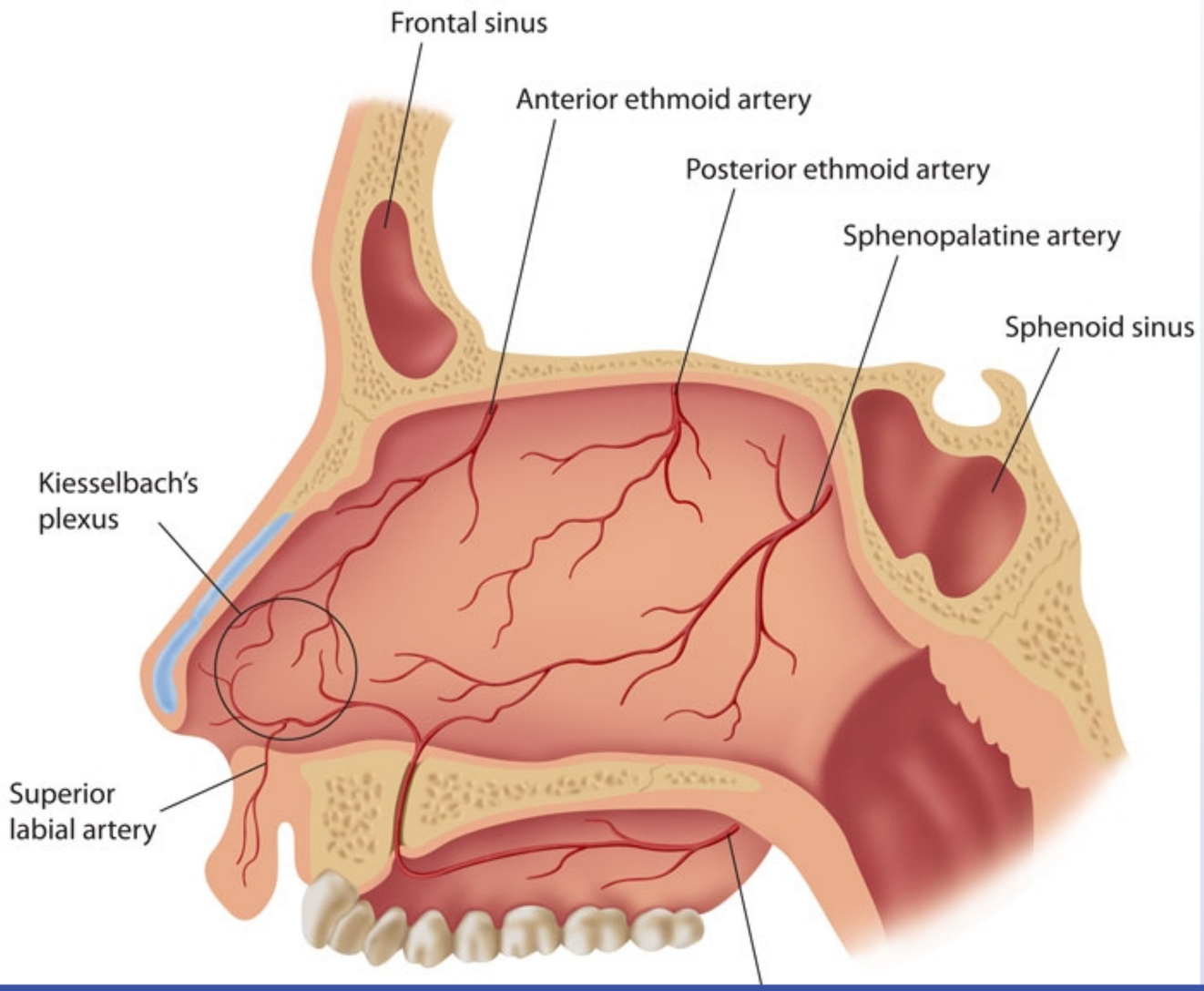

The nasal mucosa is highly vascular and easily irritated by trauma (eg, nose-picking), mucosal dryness, foreign body insertion, and rhinitis (eg, allergy, infection). **Epistaxis** is very common in children and may be classified as anterior or posterior, depending on the bleeding source. Anterior nosebleeds are by far the most common, and the vast majority occur within the vascular watershed area of the **nasal septum** (anteroinferior part of the nasal septal mucosa) known as **Kiesselbach plexus**. Anastomosis of the following vessels occurs in this region:

- Septal branch of the **anterior ethmoidal artery**
- Lateral nasal branch of the **sphenopalatine artery**
- Septal branch of the **superior labial artery** (branch of the facial artery)

Management is directed at stopping the bleeding from Kiesselbach plexus, preferably by direct compression of the nasal alae. Cautery (eg, silver nitrate) of the area surrounding the bleeding site may be necessary for persistent bleeding.

(Choices A and B) The lateral nasal wall contains the superior, middle, and inferior turbinates (also known as conchae). These 3 bony projections are covered with mucous membrane; they warm, humidify, and filter inspired air and expand and contract in response to environmental changes (eg, temperature, humidity, allergens). The turbinates form corresponding meatuses that serve as drainage pathways. The superior meatus provides drainage for the sphenoidal and posterior ethmoidal sinuses. The middle meatus drains the frontal, maxillary, and anterior ethmoidal sinuses and is the most common site of nasal polyps. The inferior meatus drains the nasolacrimal duct.

(Choices D and E) Branches of the sphenopalatine artery supply the posterolateral wall and posterior choanae. These posterolateral branches are the most likely source of posterior nosebleeds. Posterior epistaxis is usually severe and cannot be treated with cautery.

Educational objective:
Epistaxis is commonly caused by irritation of the highly vascular mucosa at the anterior nasal septum. The anterior nasal septum contains the Kiesselbach plexus. The anterior ethmoidal, sphenopalatine, and superior labial arteries anastomose in this region.

References

- Fifteen-minute consultation: investigation and management of childhood epistaxis.
- Interventions for recurrent idiopathic epistaxis (nosebleeds) in children.

Anatomy Ear, Nose & Throat (ENT) Epistaxis

The nasal mucosa is highly vascular and easily irritated by trauma (eg, nose-picking), mucosal dryness, foreign body insertion, and rhinitis (eg

Exhibit Display

How to stop epistaxis

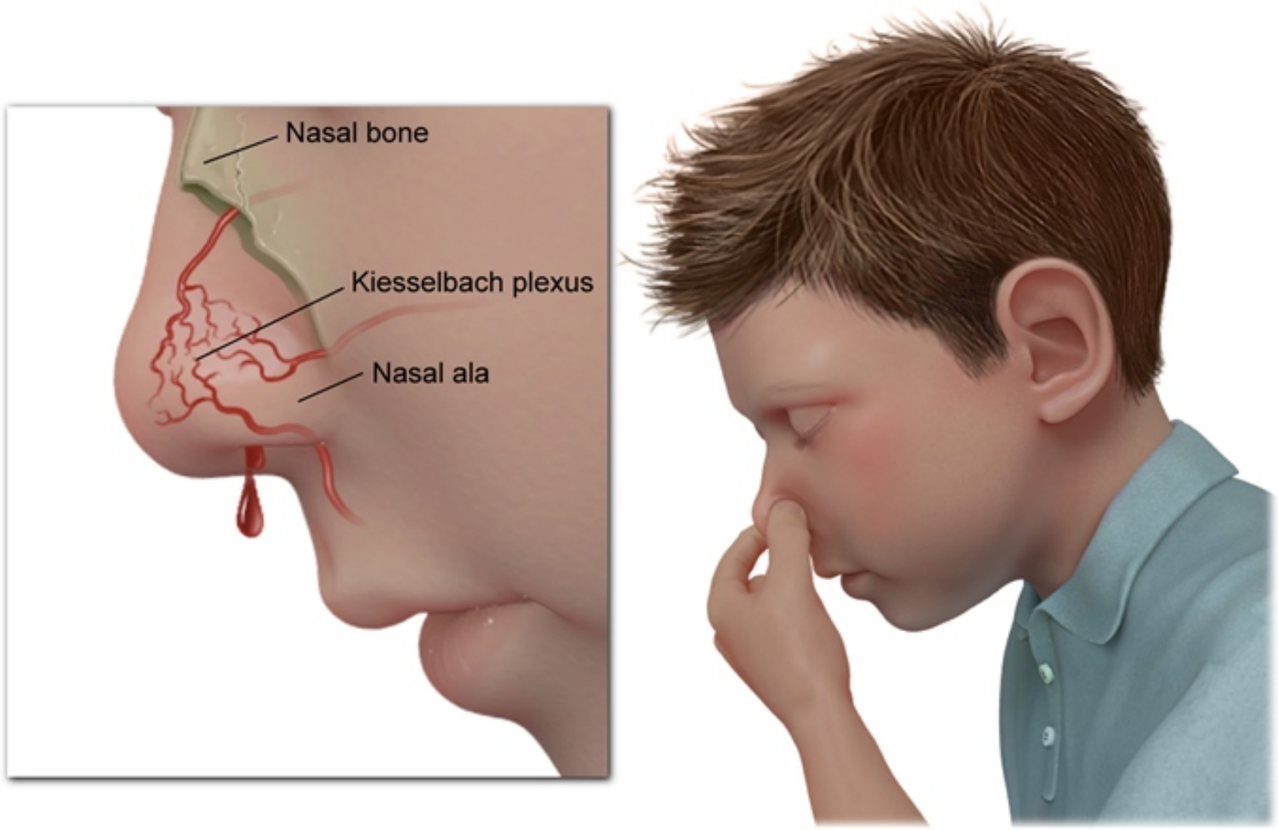

Nasal alae are compressed to stop blood flow.

©UWorld

Zoom In | Zoom Out | Reset | Add To New Card | Existing Card

Anatomy | Ear, Nose & Throat (ENT) | Epistaxis

The nasal mucosa is highly vascular and easily irritated by trauma (eg, nose-picking), mucosal dryness, foreign body insertion, and rhinitis (eg

Exhibit Display

Anatomy of the nasal cavity & nasopharynx

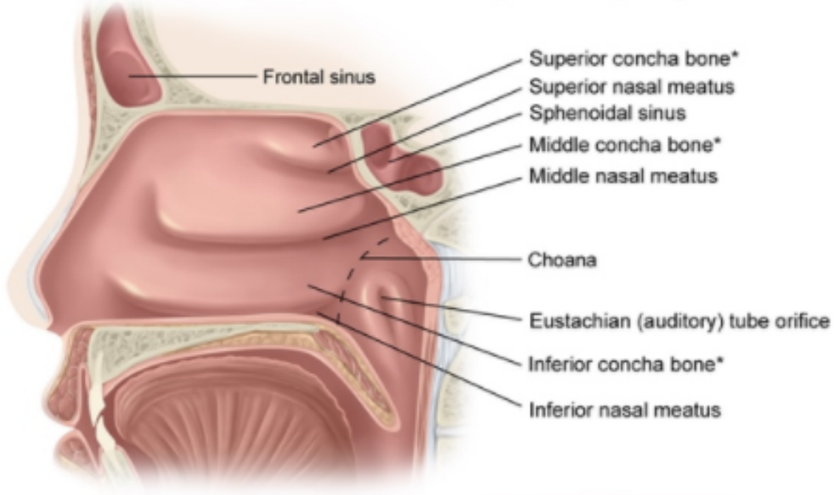

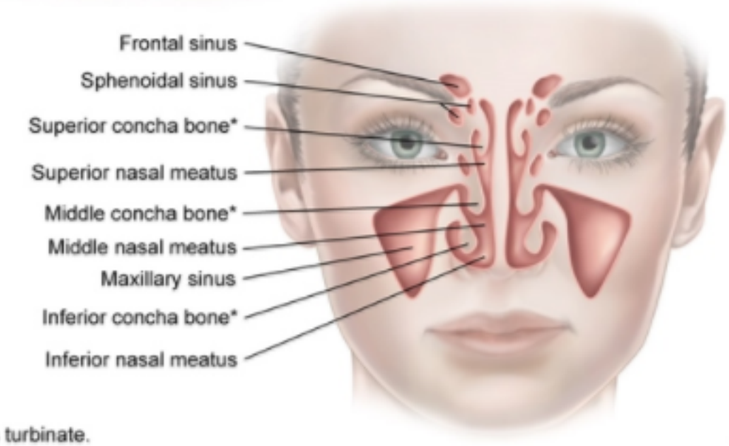

*Also known as turbinate.

©UWorld

Zoom In | Zoom Out | Reset | Add To New Card | Existing Card

Anatomy | Ear, Nose & Throat (ENT) | Epistaxis